

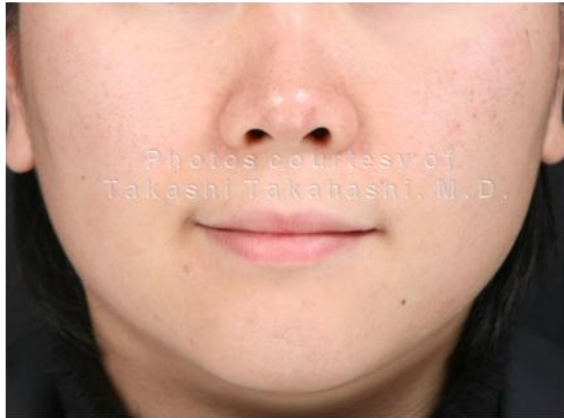FRM™ Technology  
Fractional Radiofrequency MicroNeedle

***INTRAcel***

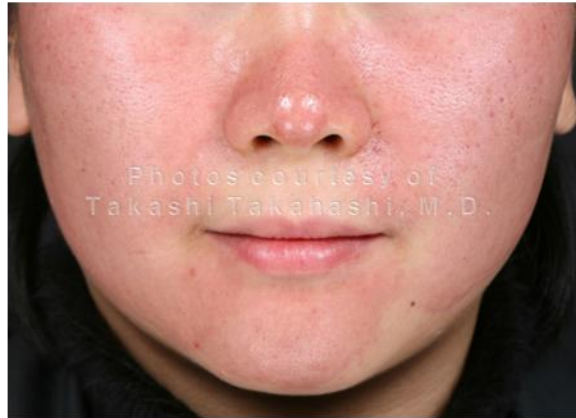***INTRAcel***

Clinical result of INTRAcel. 

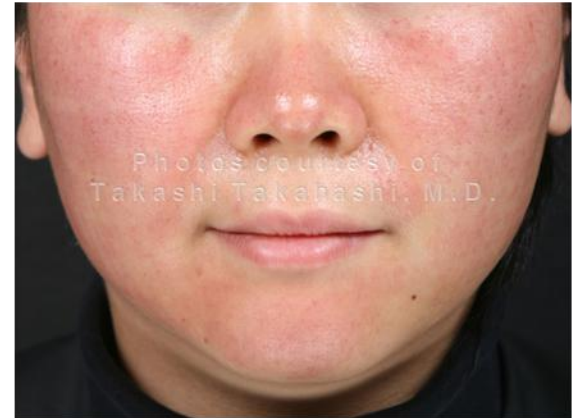## Change after treatment



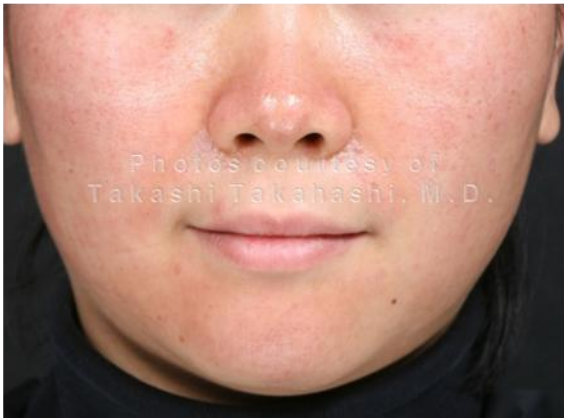Before  
Treatment



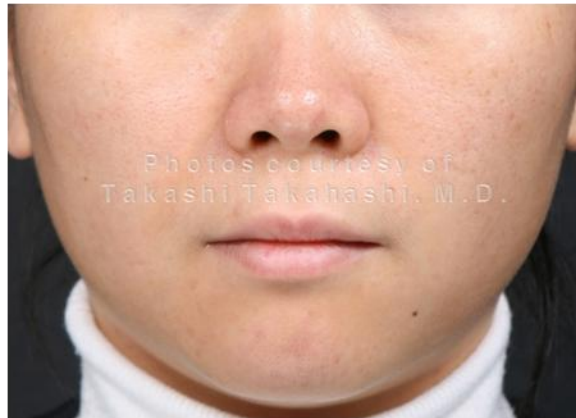Immediate after  
Treatment



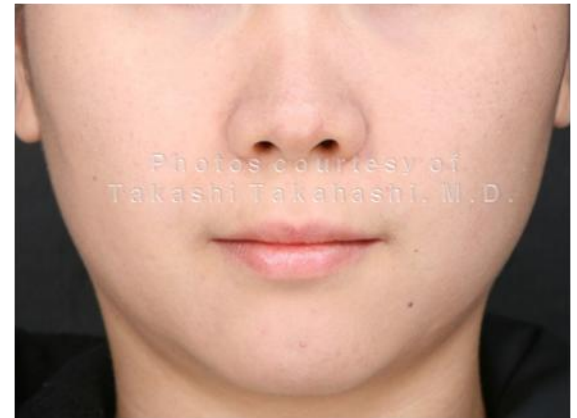1 days after  
Treatment



2 days after  
Treatment



4 days after  
Treatment



6 days after  
Treatment

# Clinical result of INTRAcel

**Scar**

# Scar

## Dr. Takashi Takahashi

*Takashi Takahashi Clinic, Tokyo, JAPAN*

# INTRAcE<sup>l</sup>

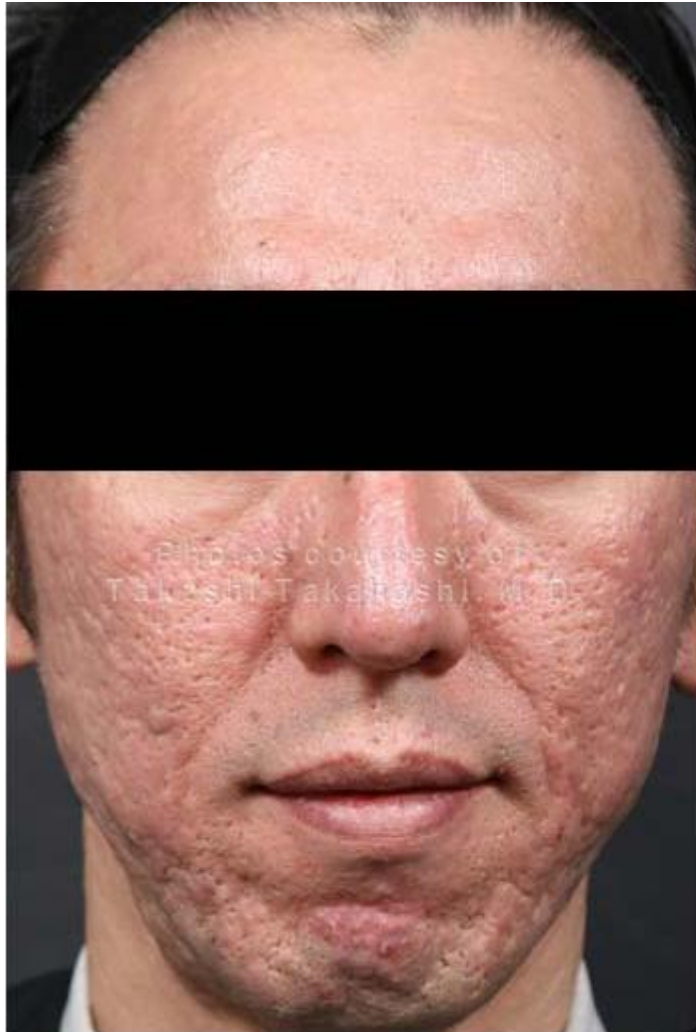
**42, Male**

**1<sup>st</sup> treatment 01/16/2009**

**2<sup>nd</sup> treatment 02/20/2009**

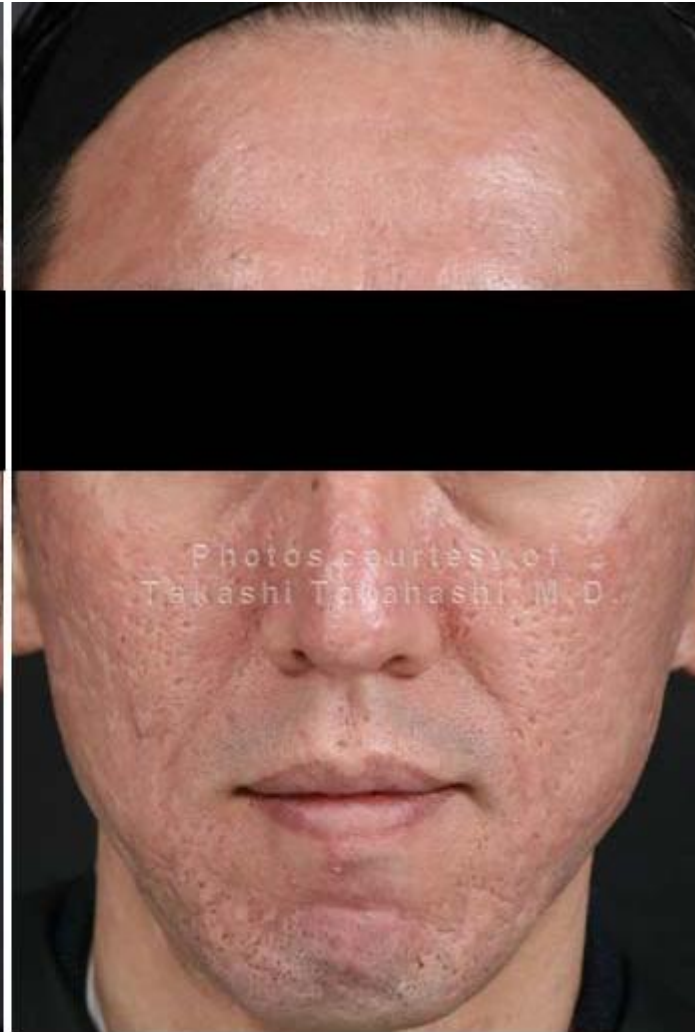**3<sup>rd</sup> treatment 03/27/2009**

Full face : Bipolar Level 3 - 0.8/1.5mm, 1/3 overlap



Photos courtesy of  
Takashi Takahashi, M.D.

**Before Treatment**



Photos courtesy of  
Takashi Takahashi, M.D.

**34 days after 1<sup>st</sup> Treatment**

# Scar

**Dr. Takashi Takahashi**

*Takashi Takahashi Clinic, Tokyo, JAPAN*

# INTRAcel

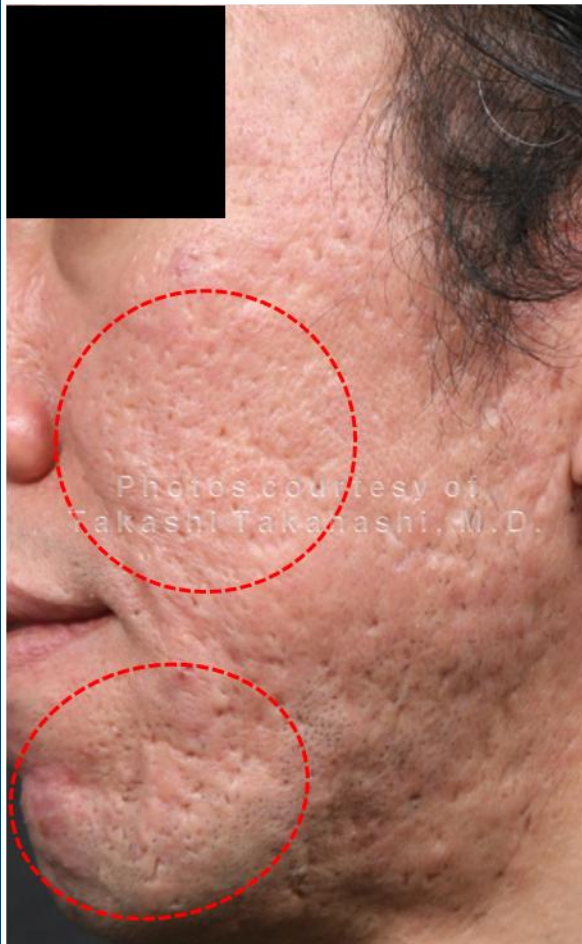**42, Male**

**1<sup>st</sup> treatment 01/16/2009**

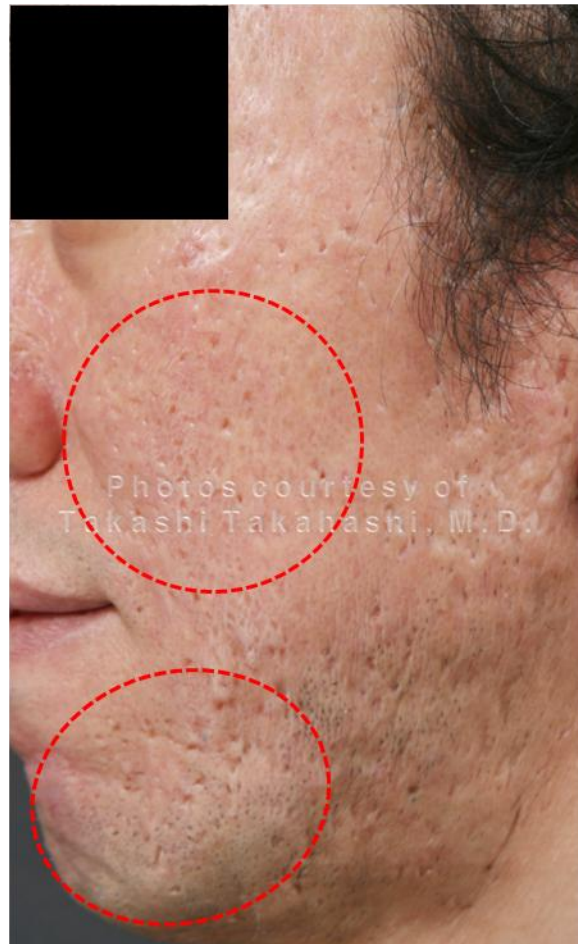**2<sup>nd</sup> treatment 02/20/2009**

**3<sup>rd</sup> treatment 03/27/2009**

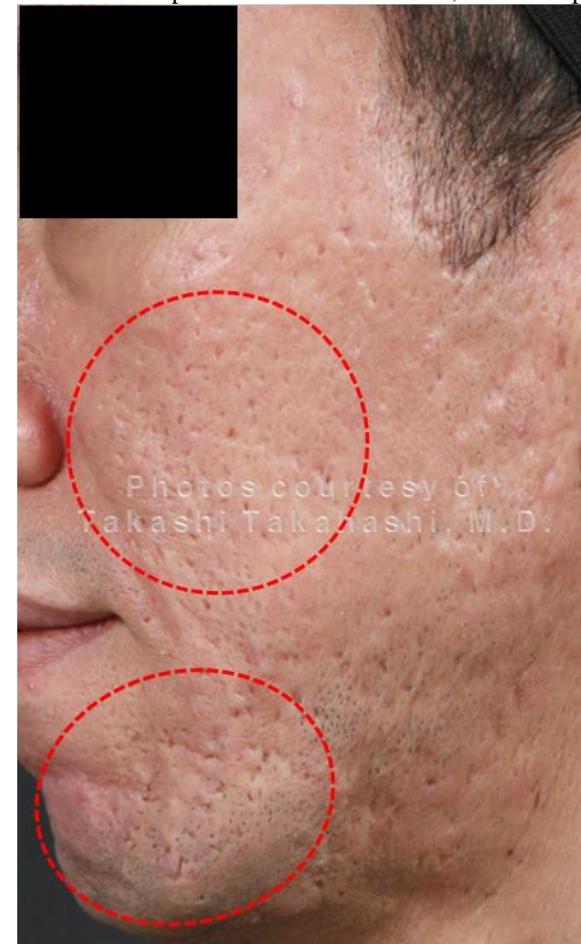Full face : Bipolar Level 3 - 0.8/1.5mm, 1/3 overlap



**Before  
Treatment**



**7 days after  
1<sup>st</sup> Treatment**



**34 days after  
1<sup>st</sup> Treatment**

# Scar

**Dr. Takashi Takahashi**

*Takashi Takahashi Clinic, Tokyo, JAPAN*

# INTRAcnel

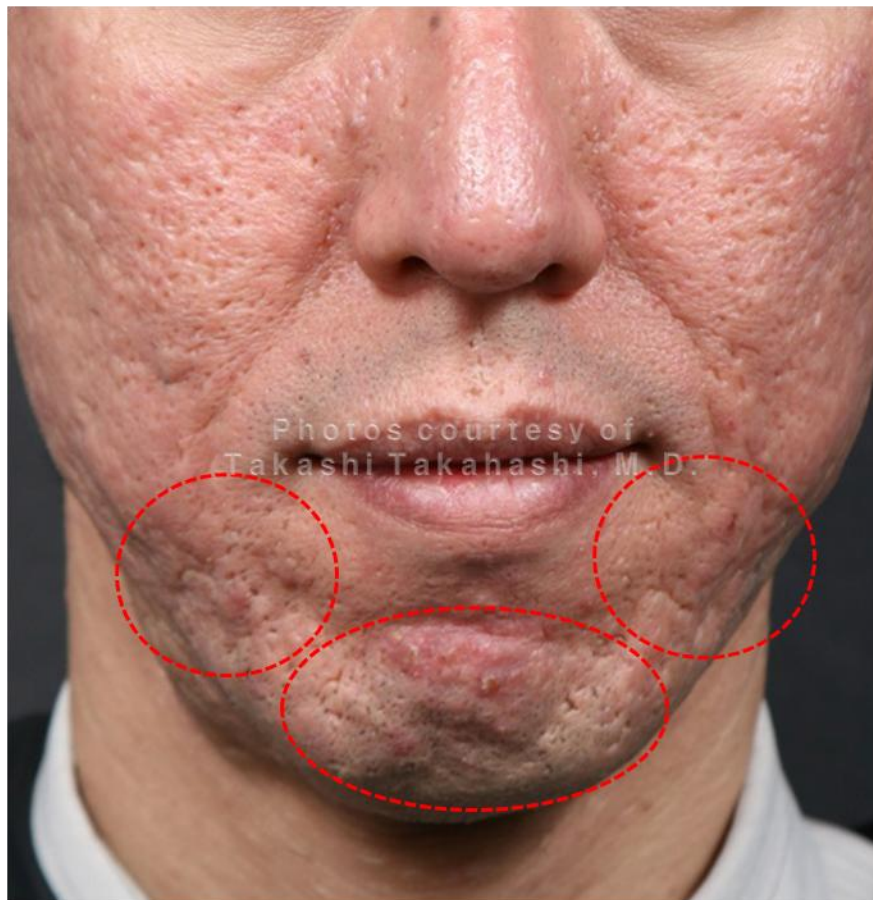**42, Male**

**1<sup>st</sup> treatment 01/16/2009**

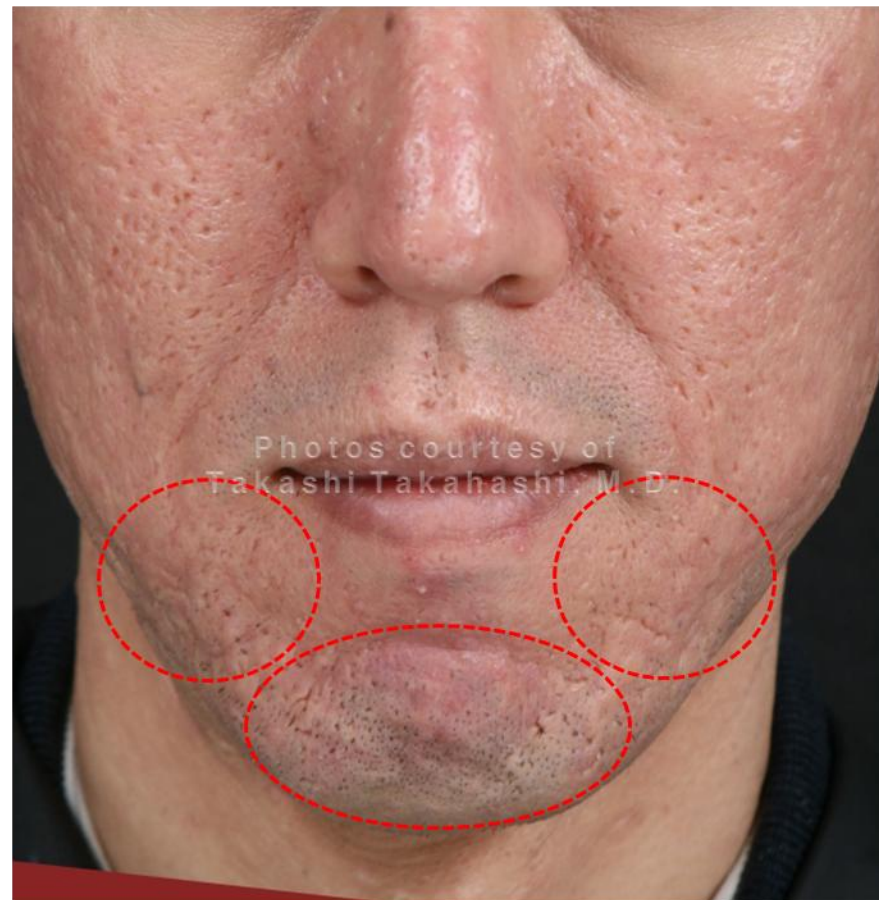
**2<sup>nd</sup> treatment 02/20/2009**

**3<sup>rd</sup> treatment 03/27/2009**

Full face : Bipolar Level 3 - 0.8/1.5mm, 1/3 overlap



**Before  
Treatment**



**34 days after  
1<sup>st</sup> Treatment**

# Scar

**Dr. Takashi Takahashi**

*Takashi Takahashi Clinic, Tokyo, JAPAN*

# INTRAcel

**42, Male**

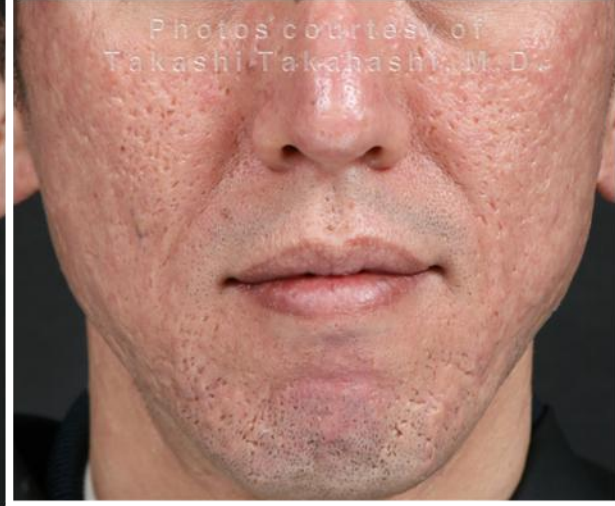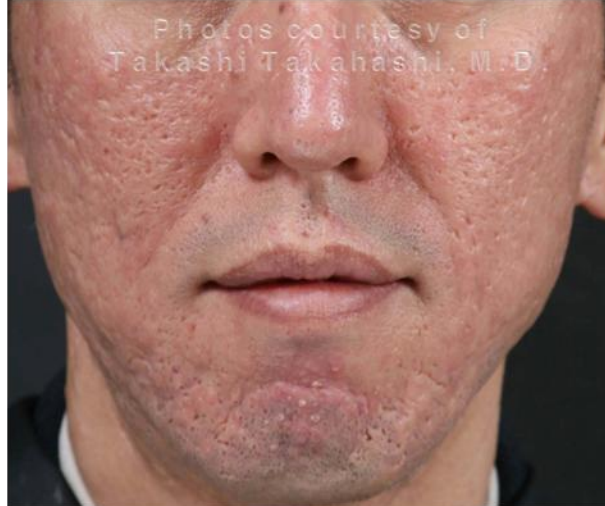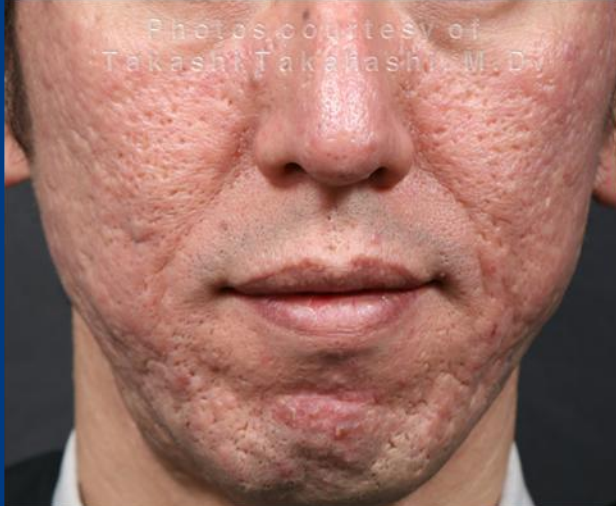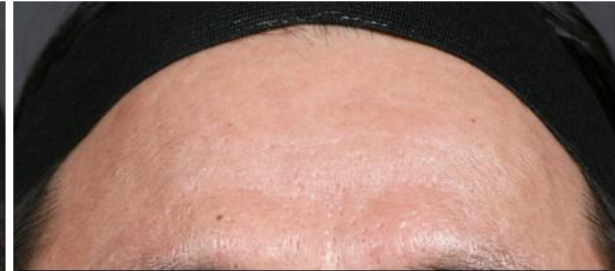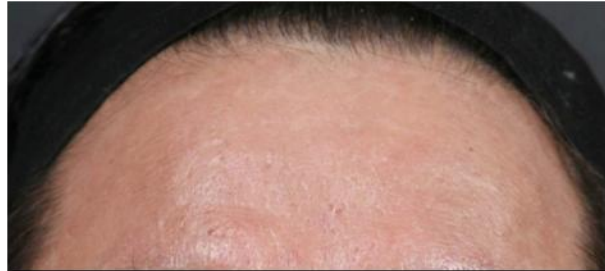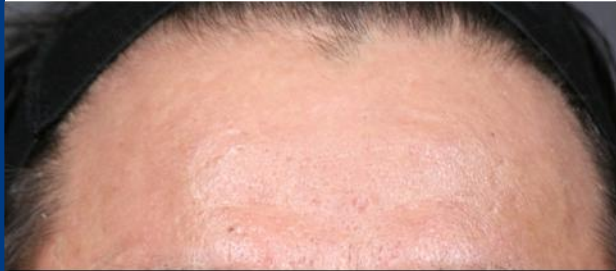1<sup>st</sup> treatment 01/16/2009

**2<sup>nd</sup> treatment 02/20/2009**

3<sup>rd</sup> treatment 03/27/2009

Full face : Bipolar Level 3 - 0.8/1.5mm, 1/2 overlap

Pore, Scar : 3 Level - 2.0mm



**Jeisy** Before Treatment

7 days after  
2<sup>nd</sup> treatment

21 days after  
2<sup>nd</sup> treatment

# Scar

## Dr. Takashi Takahashi

Takashi Takahashi Clinic, Tokyo, JAPAN

# INTRAcE<sup>l</sup>

42, Male

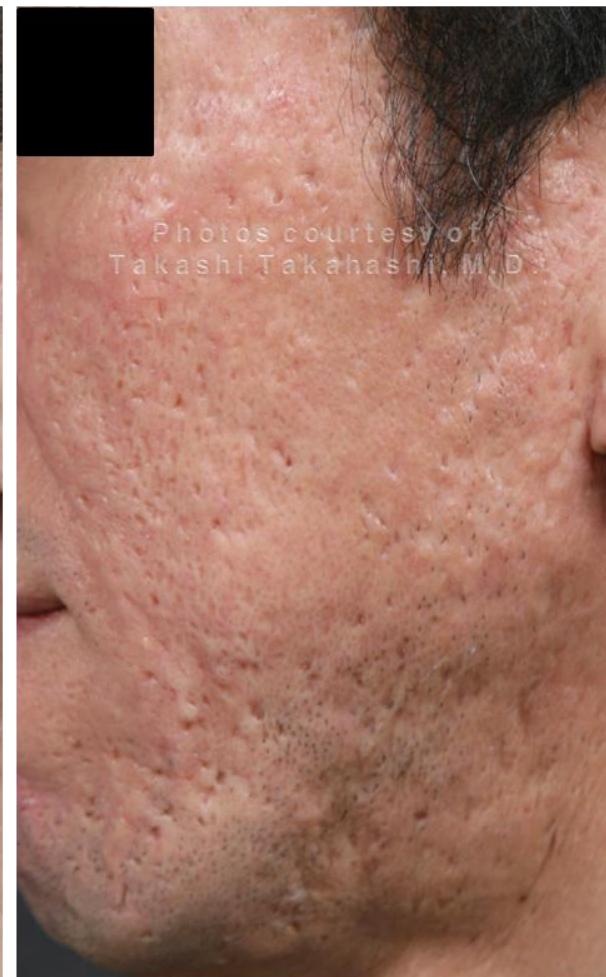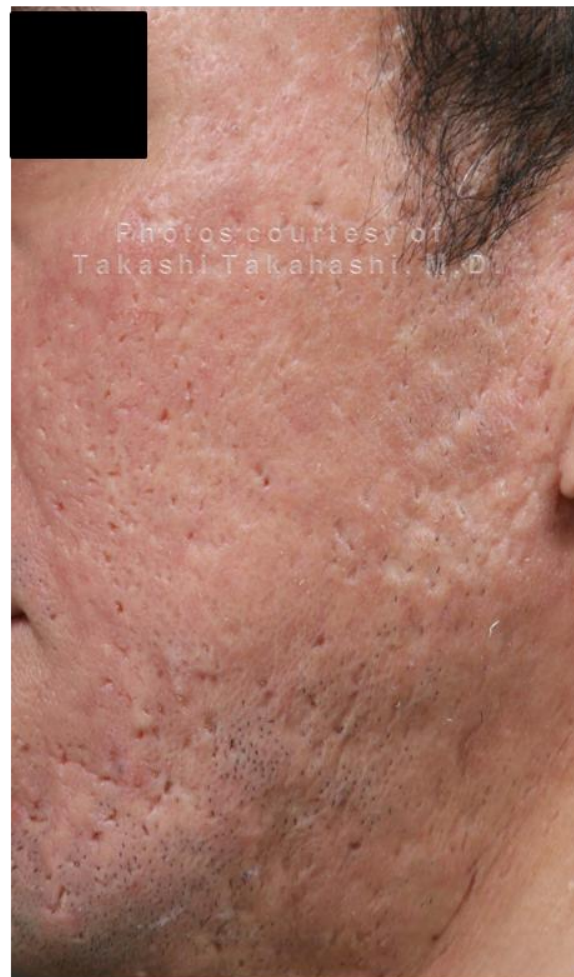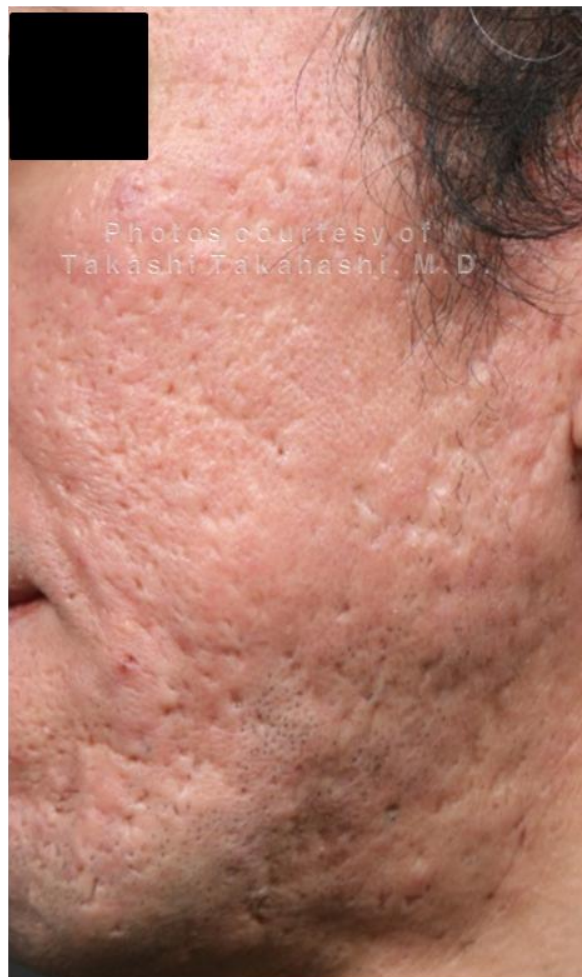1<sup>st</sup> treatment 01/16/2009

2<sup>nd</sup> treatment 02/20/2009

3<sup>rd</sup> treatment 03/27/2009

Full face : Bipolar Level 3 - 0.8/1.5mm, 1/2 overlap

Pore, Scar : 3 Level - 2.0mm



Jeisys Before Treatment

7 days after  
2<sup>nd</sup> treatment

21 days after  
2<sup>nd</sup> treatment



# Scar

**Dr. Takashi Takahashi**

*Takashi Takahashi Clinic, Tokyo, JAPAN*

# INTRAcnel

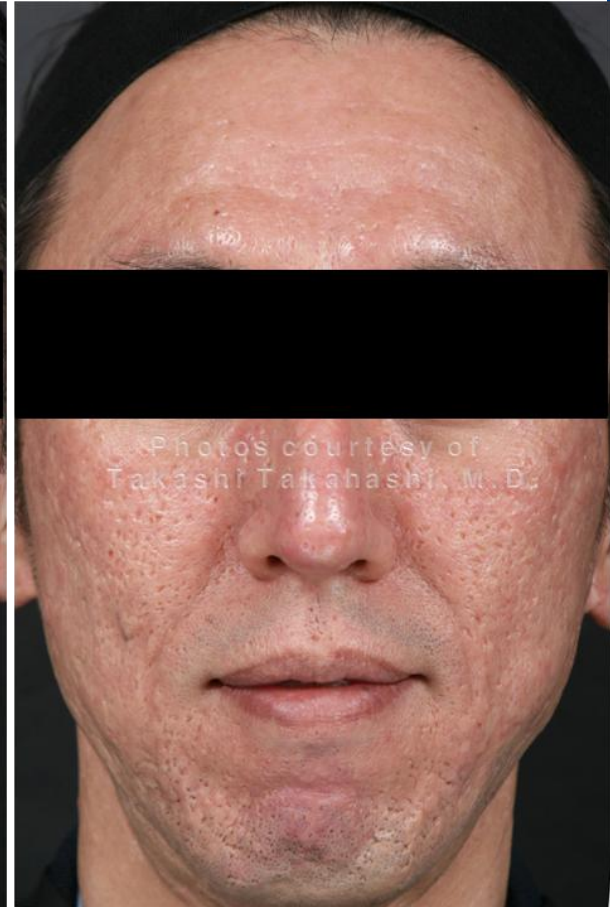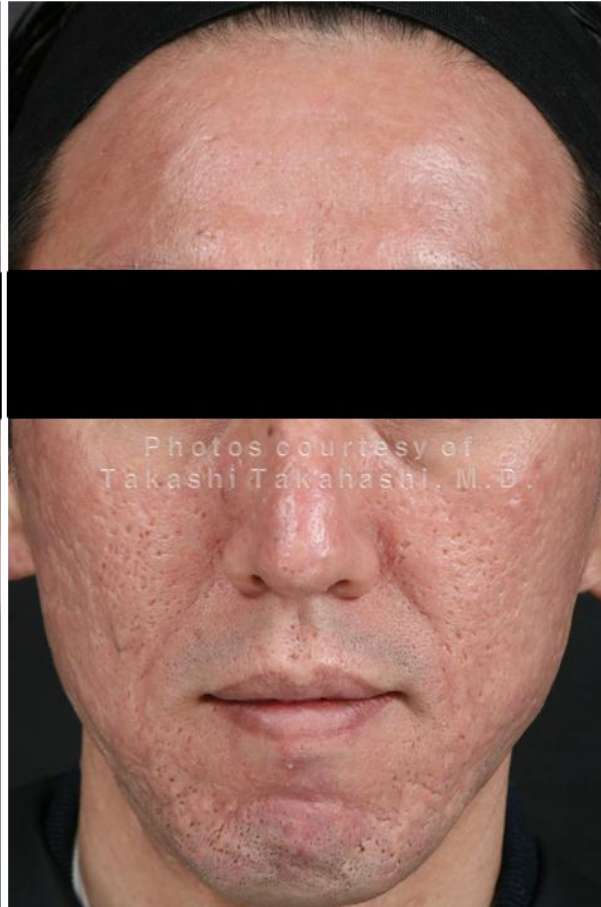
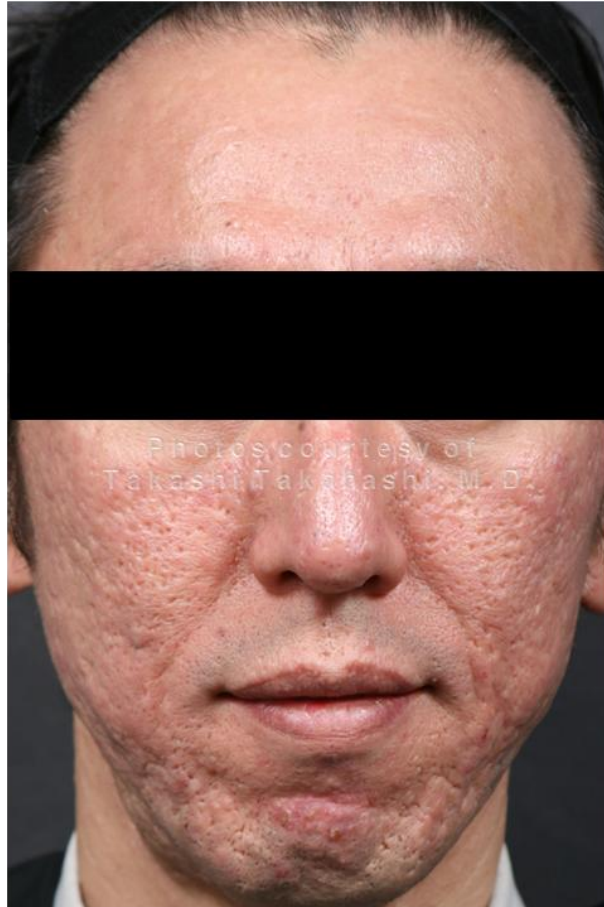**42, Male**

1<sup>st</sup> treatment 01/16/2009

2<sup>nd</sup> treatment 02/20/2009

**3<sup>rd</sup> treatment 03/27/2009**

Full face : Bipolar Level 2 - 0.8/1.5mm, 1/2 overlap



**Jeisys** Before Treatment

Before 2<sup>nd</sup> Treatment

Before 3<sup>rd</sup> Treatment

# Scar

**Dr. Takashi Takahashi**

*Takashi Takahashi Clinic, Tokyo, JAPAN*

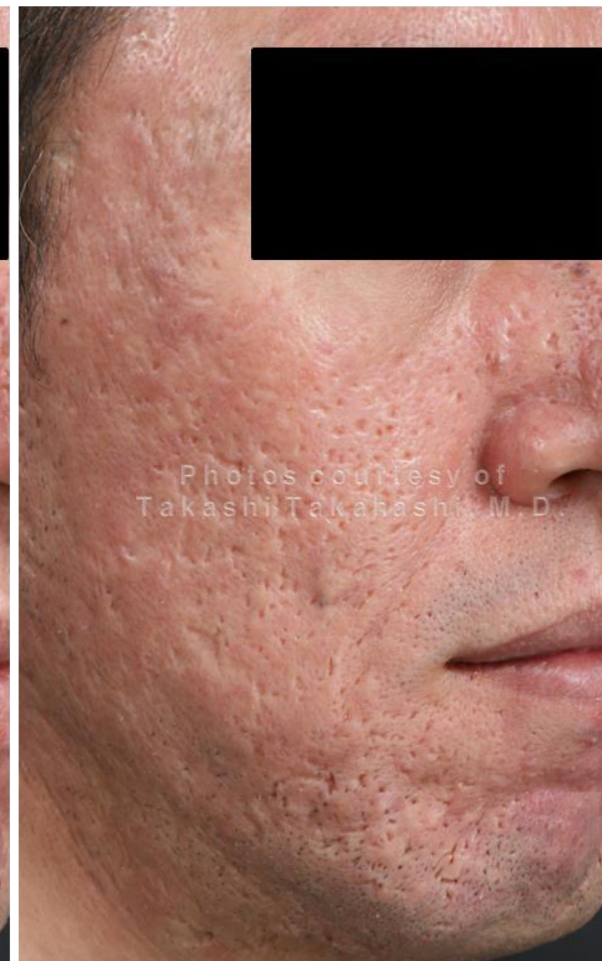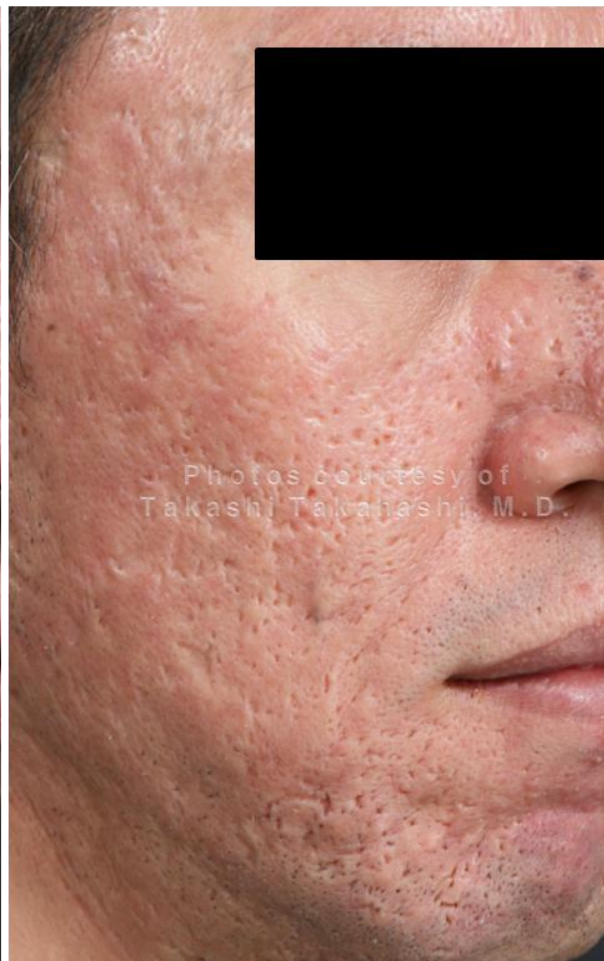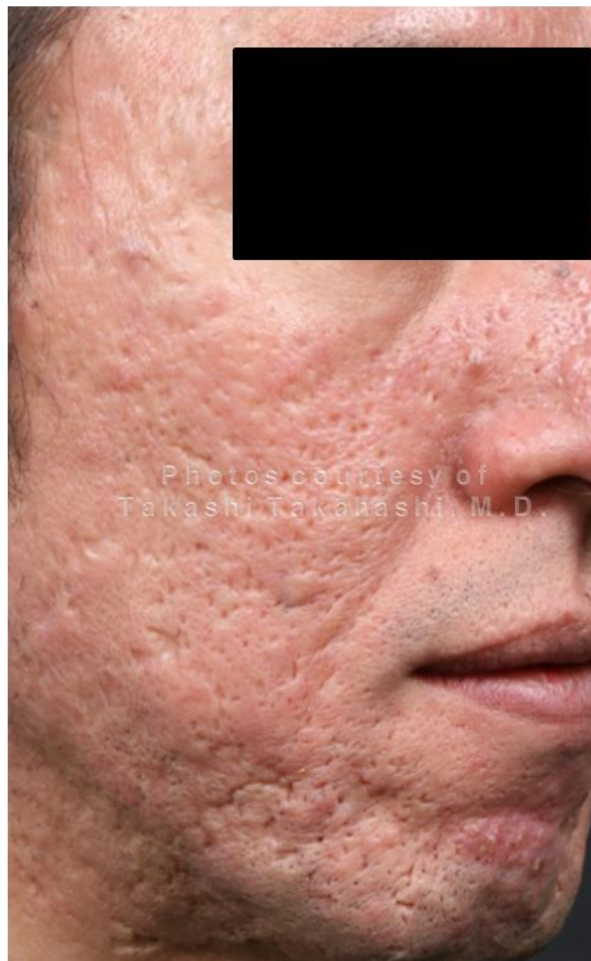# INTRAcel

**42, Male**

1<sup>st</sup> treatment 01/16/2009

2<sup>nd</sup> treatment 02/20/2009

3<sup>rd</sup> treatment 03/27/2009



**Before Treatment**

**Before 2<sup>nd</sup> Treatment**

**Before 3<sup>rd</sup> Treatment**

# Scar

## Dr. Takashi Takahashi

Takashi Takahashi Clinic, Tokyo, JAPAN

# INTRAcE<sup>l</sup>

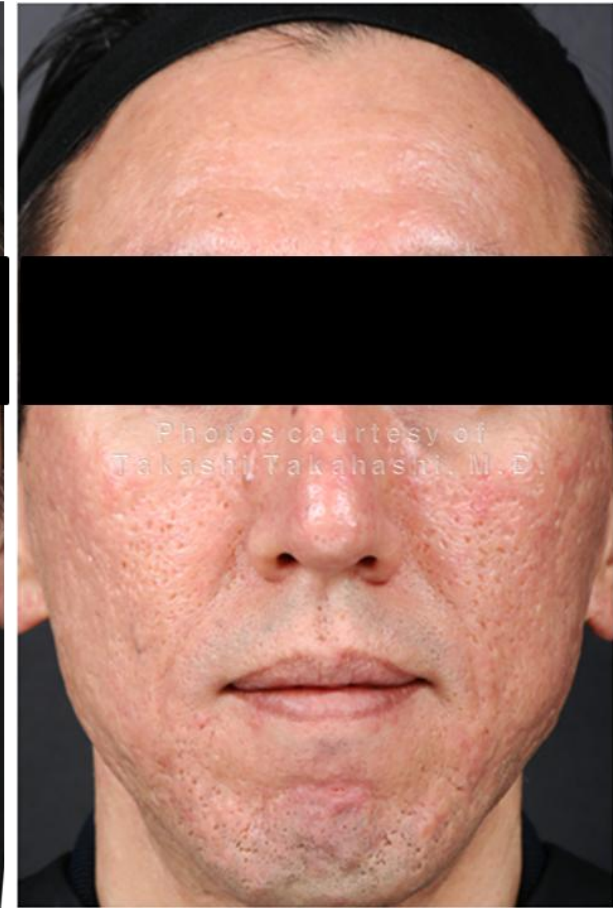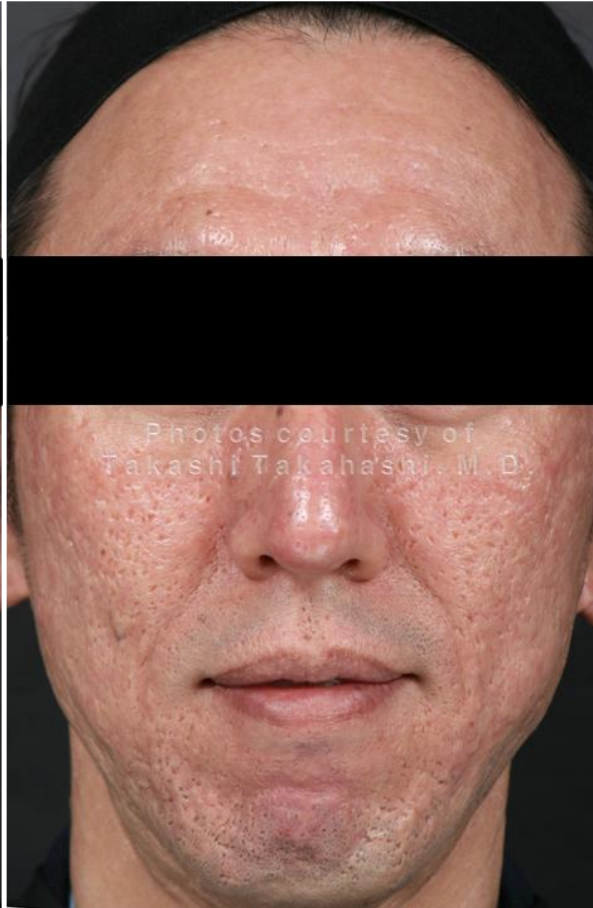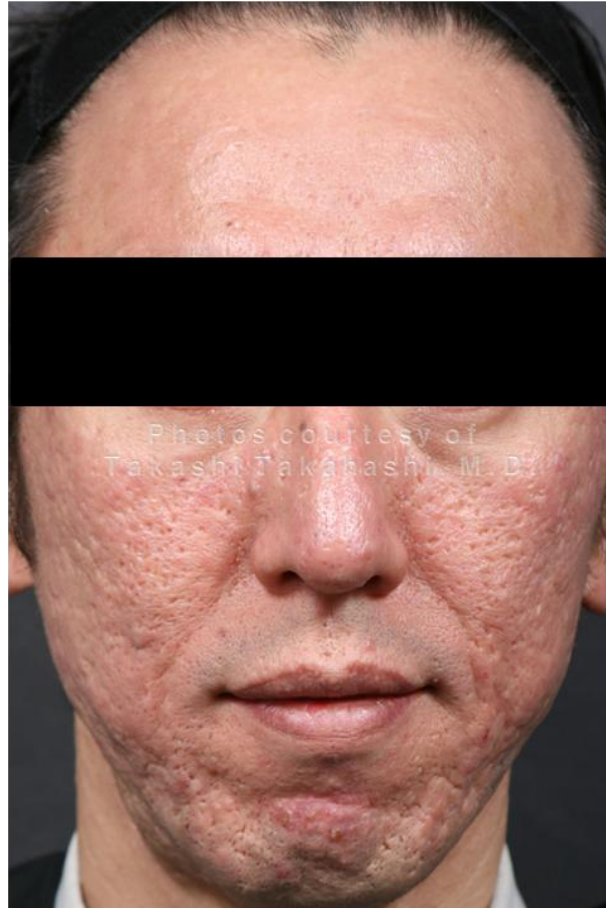42, Male

1<sup>st</sup> treatment 01/16/2009

2<sup>nd</sup> treatment 02/20/2009

3<sup>rd</sup> treatment 03/27/2009

Full face : Bipolar Level 3 - 0.8/1.5mm, 1/2 overlap



Before Treatment

Before 3<sup>rd</sup> Treatment

Before 4<sup>th</sup> Treatment

# Scar

## Dr. Takashi Takahashi

Takashi Takahashi Clinic, Tokyo, JAPAN

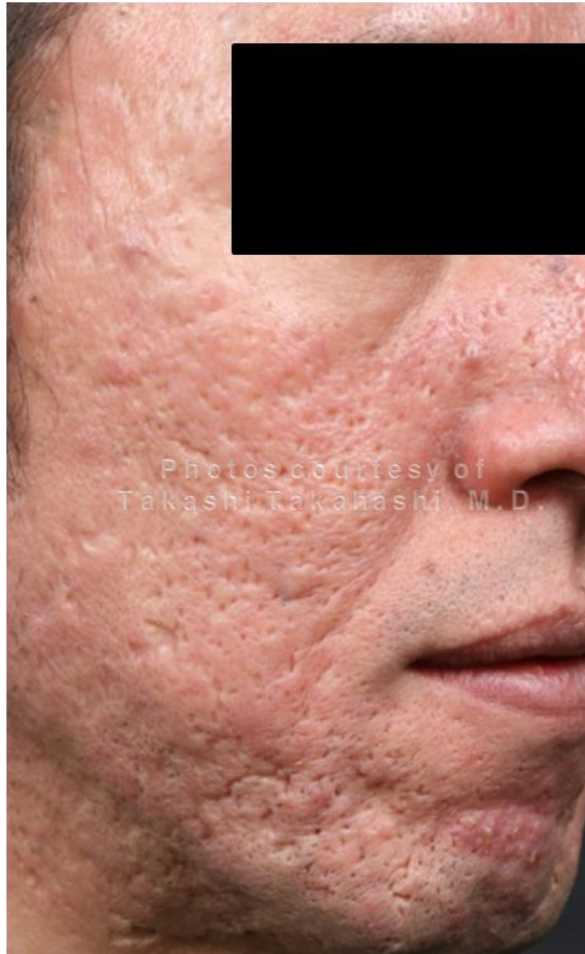# INTRAcel

42, Male

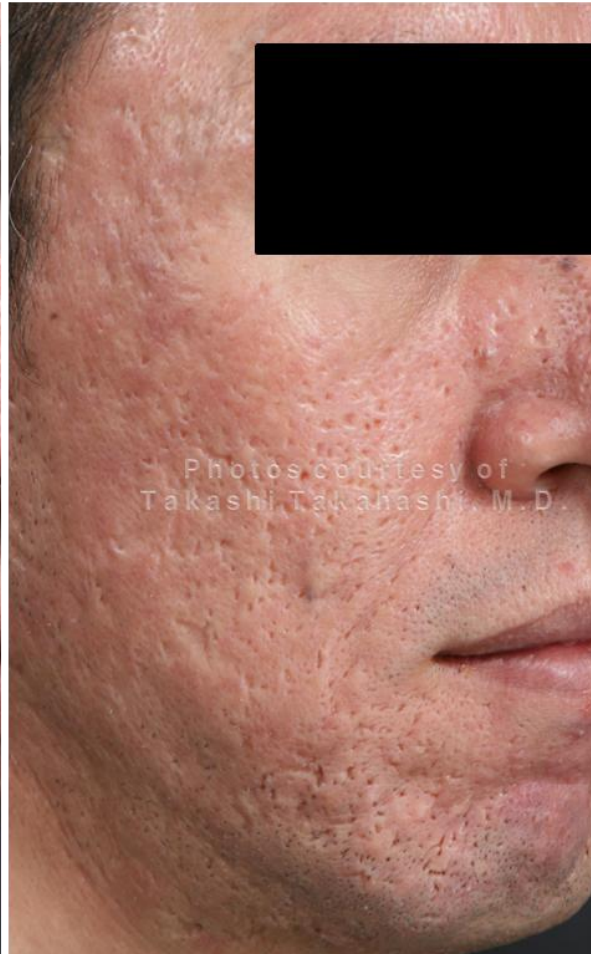1<sup>st</sup> treatment 01/16/2009

2<sup>nd</sup> treatment 02/20/2009

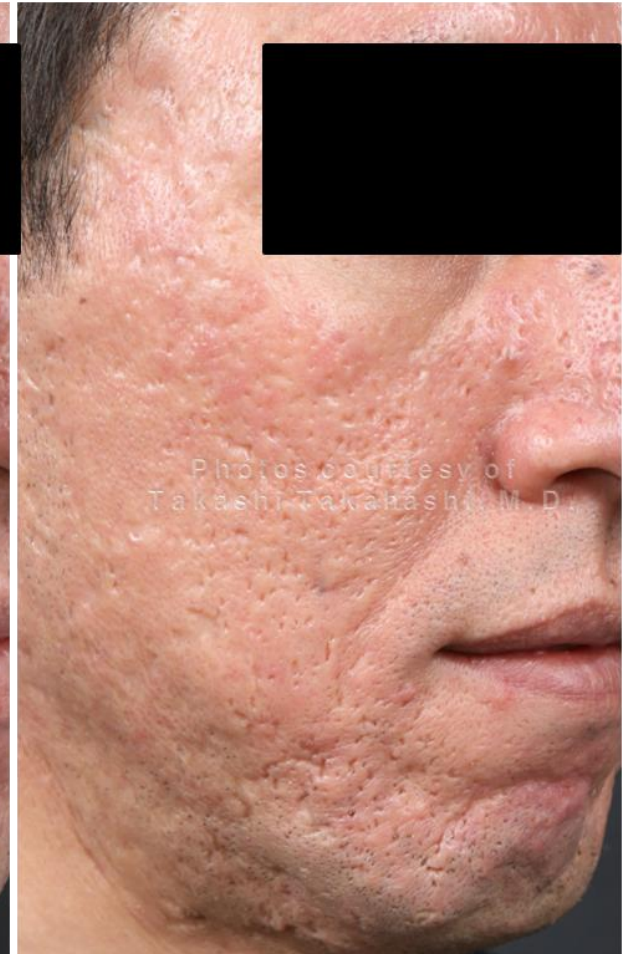3<sup>rd</sup> treatment 03/27/2009



Before Treatment



Before 3<sup>rd</sup> Treatment



Before 4<sup>th</sup> Treatment

# Scar

**Dr. Takashi Takahashi**

*Takashi Takahashi Clinic, Tokyo, JAPAN*

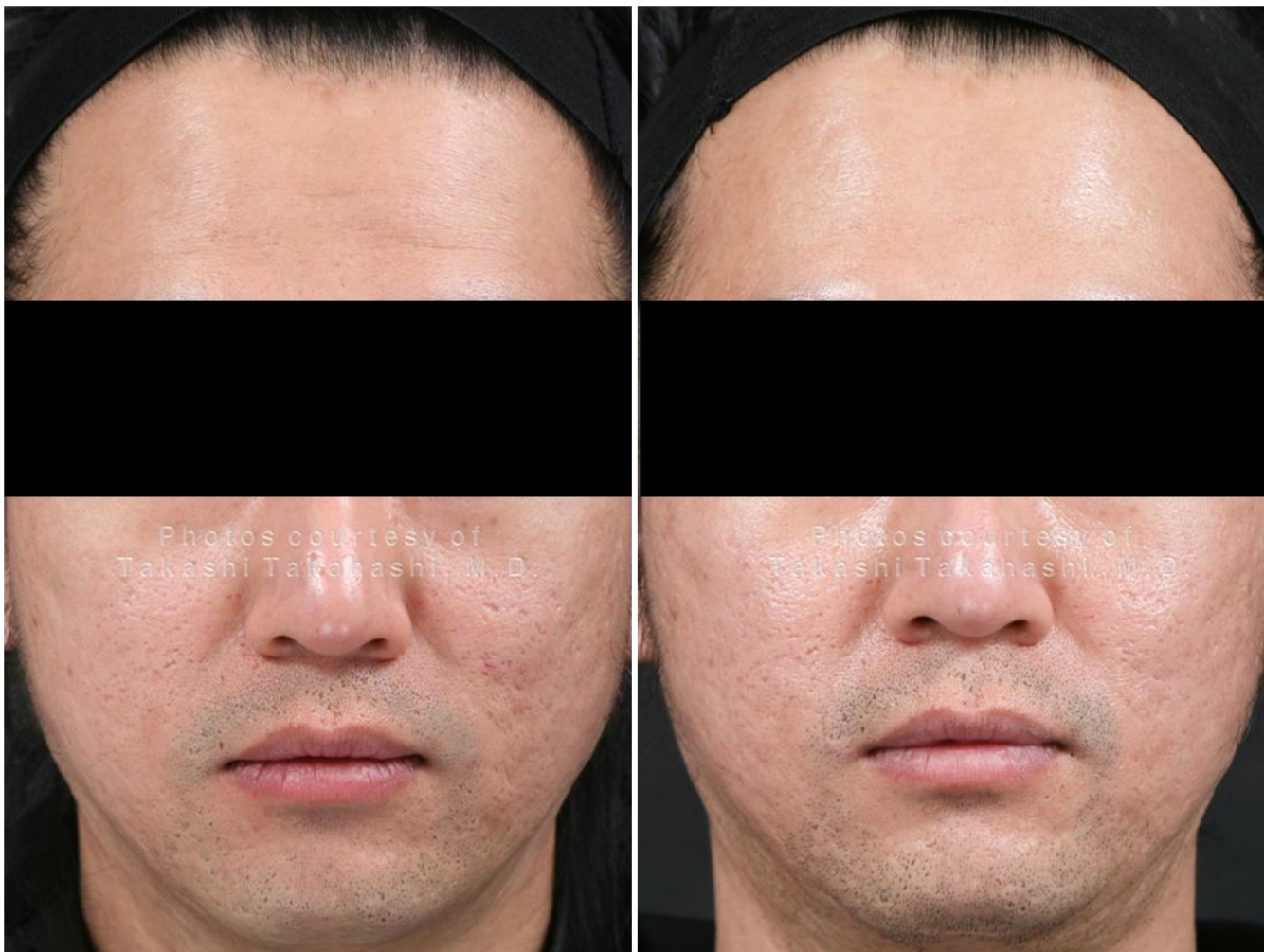# INTRAcE<sup>l</sup>

**32, Male**

1<sup>st</sup> treatment 01/16/2009

2<sup>nd</sup> treatment 02/26/2009

3<sup>rd</sup> treatment 04/07/2009



**Before  
Treatment**

**34 days after  
1<sup>st</sup> Treatment**

# Scar

**Dr. Takashi Takahashi**

*Takashi Takahashi Clinic, Tokyo, JAPAN*

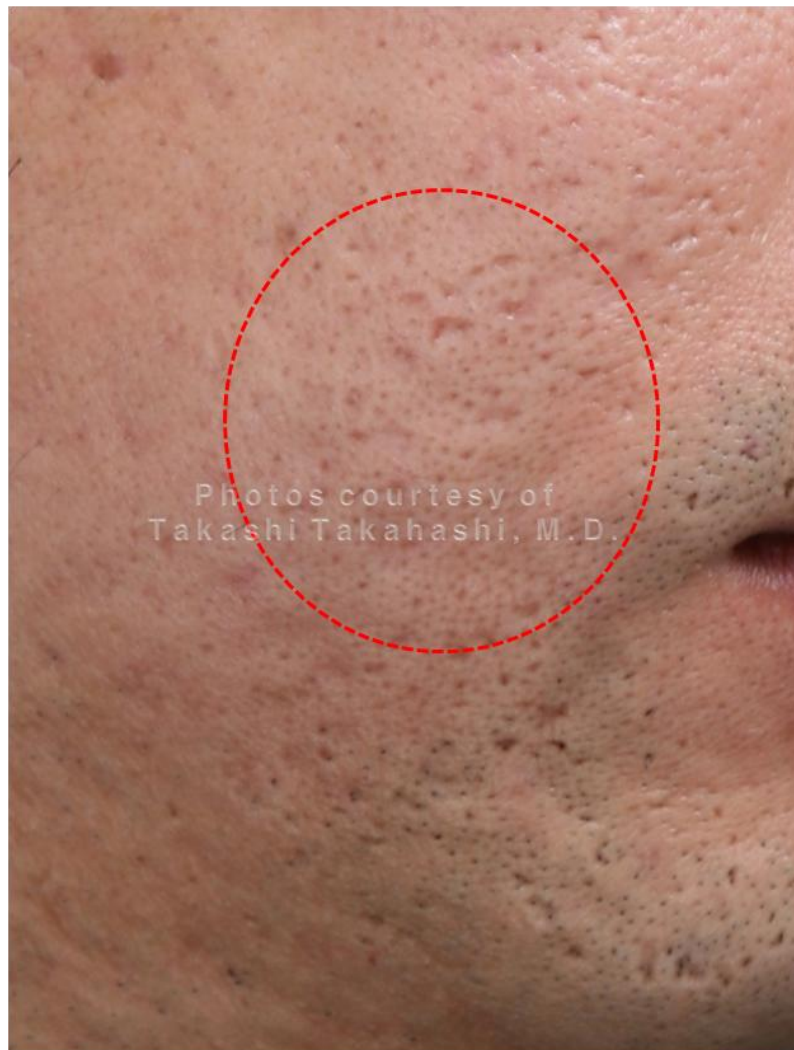# INTRAcnel

**32, Male**

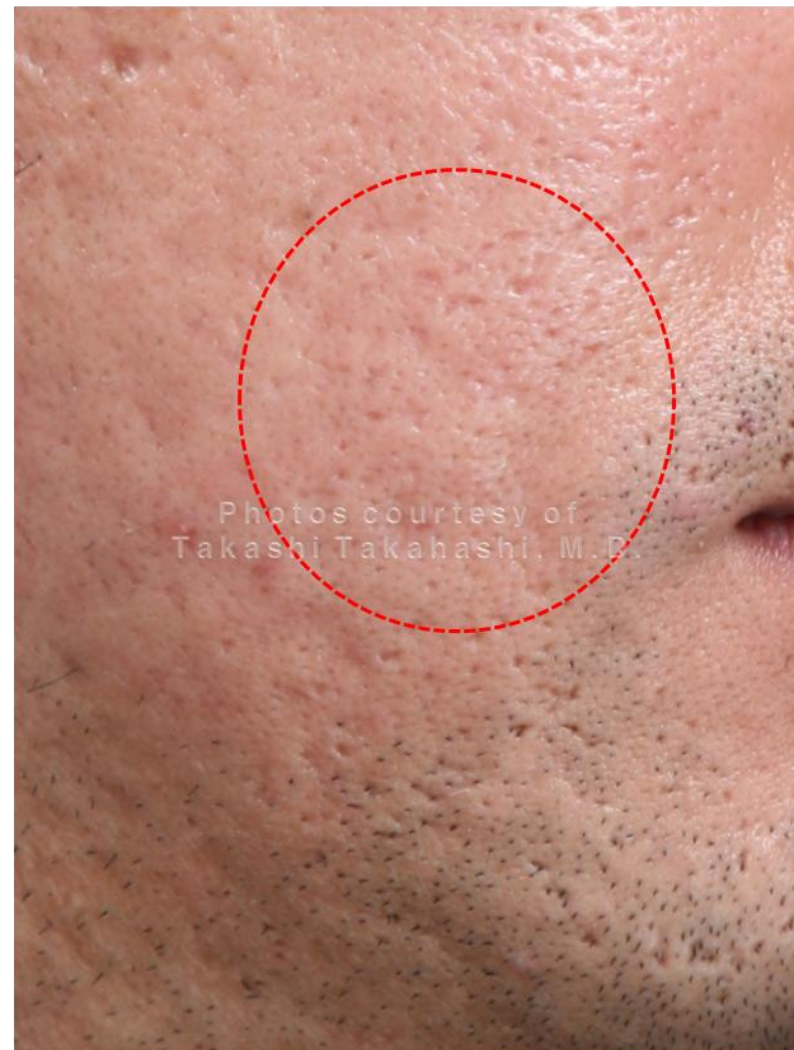1<sup>st</sup> treatment 01/16/2009

2<sup>nd</sup> treatment 02/26/2009

3<sup>rd</sup> treatment 04/07/2009



**Before  
Treatment**



**34 days after  
1<sup>st</sup> Treatment**

# Scar

## Dr. Takashi Takahashi

Takashi Takahashi Clinic, Tokyo, JAPAN

# INTRAcE<sup>l</sup>

38, Male

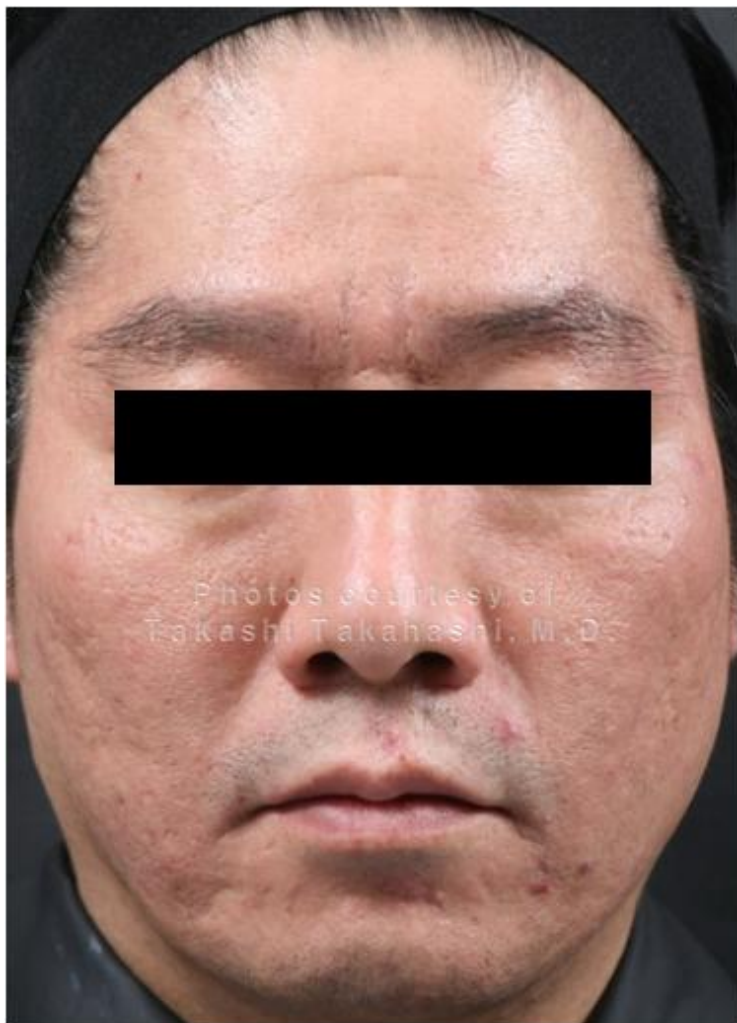1<sup>st</sup> treatment 02/10/2009

2<sup>nd</sup> treatment 03/12/2009

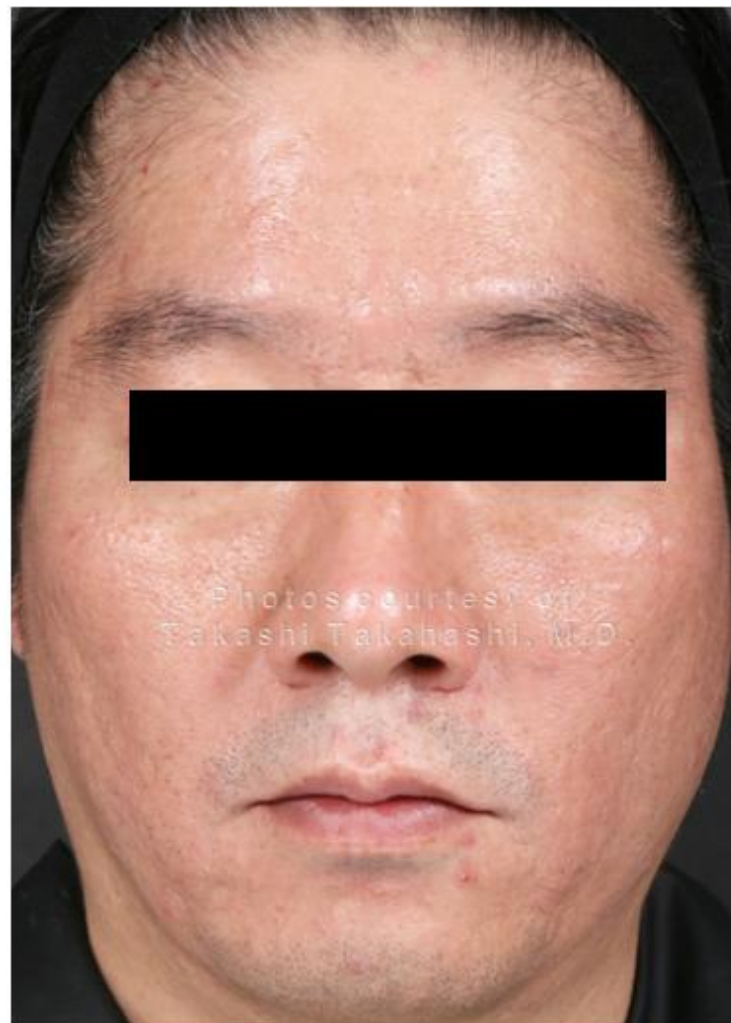3<sup>rd</sup> treatment 04/28/2009

4<sup>th</sup> treatment 06/04/2009

Full face : Bipolar Level 3 - 0.8/1.5mm, 1/2 overlap



Before Treatment



36 days after 3<sup>rd</sup> Treatment

# Scar

**Dr. Takashi Takahashi**

*Takashi Takahashi Clinic, Tokyo, JAPAN*

# INTRAcE<sup>l</sup>

**38, Male**

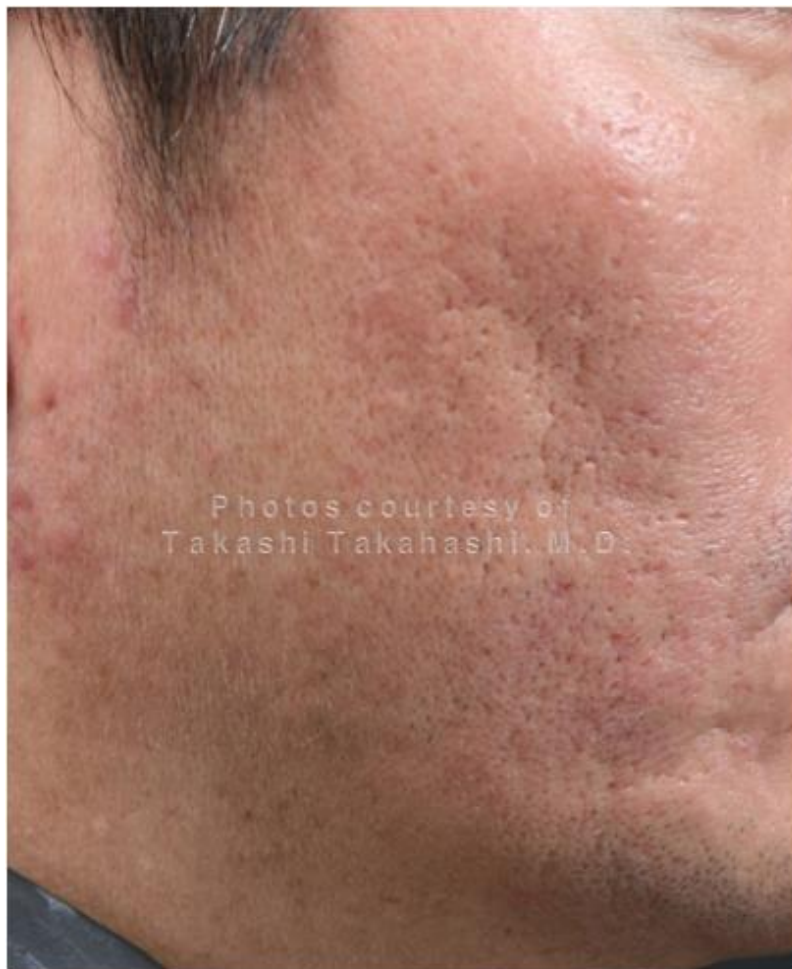1<sup>st</sup> treatment 02/10/2009

2<sup>nd</sup> treatment 03/12/2009

3<sup>rd</sup> treatment 04/28/2009

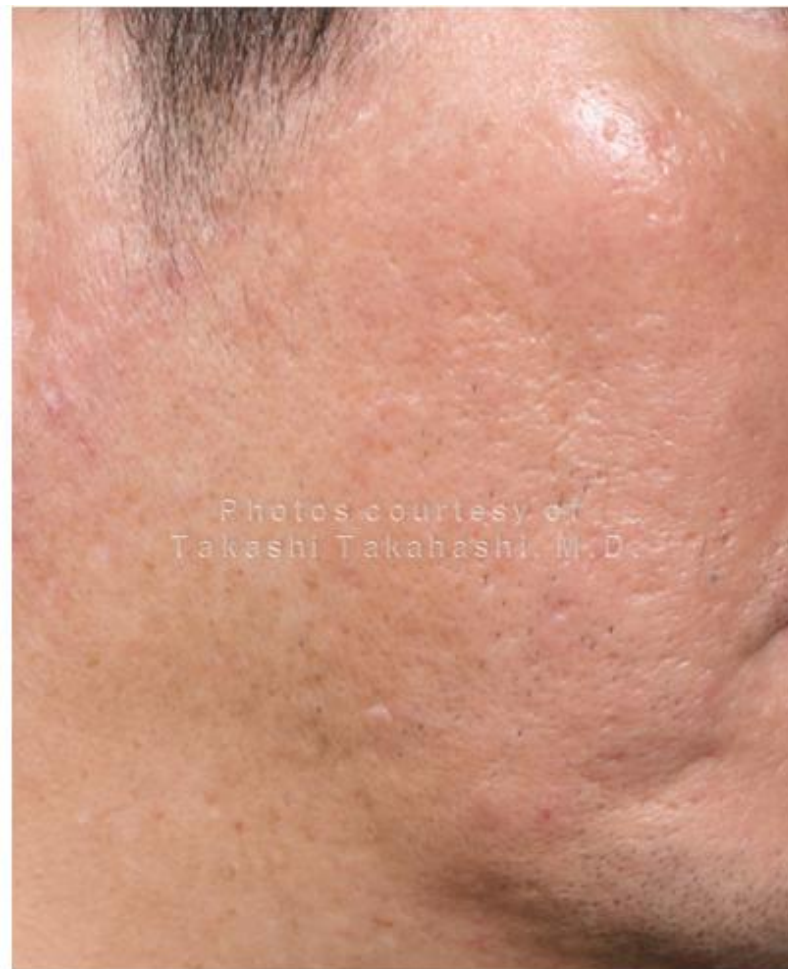4<sup>th</sup> treatment 06/04/2009

Full face : Bipolar Level 3 - 0.8/1.5mm, 1/2 overlap



Photos courtesy of  
Takashi Takahashi, M.D.

**Before Treatment**



Photos courtesy of  
Takashi Takahashi, M.D.

**Before 4<sup>th</sup> Treatment**



# Scar

## Dr. Takashi Takahashi

*Takashi Takahashi Clinic, Tokyo, JAPAN*

# INTRAcE<sup>l</sup>

**38, Male**

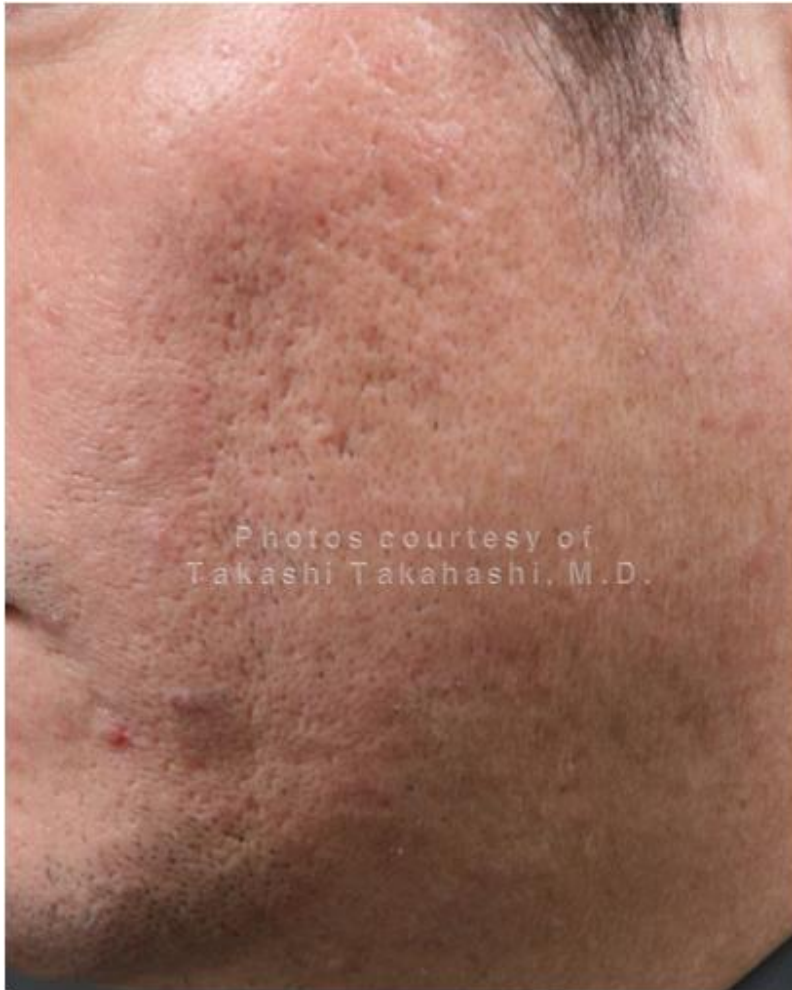1<sup>st</sup> treatment 02/10/2009

2<sup>nd</sup> treatment 03/12/2009

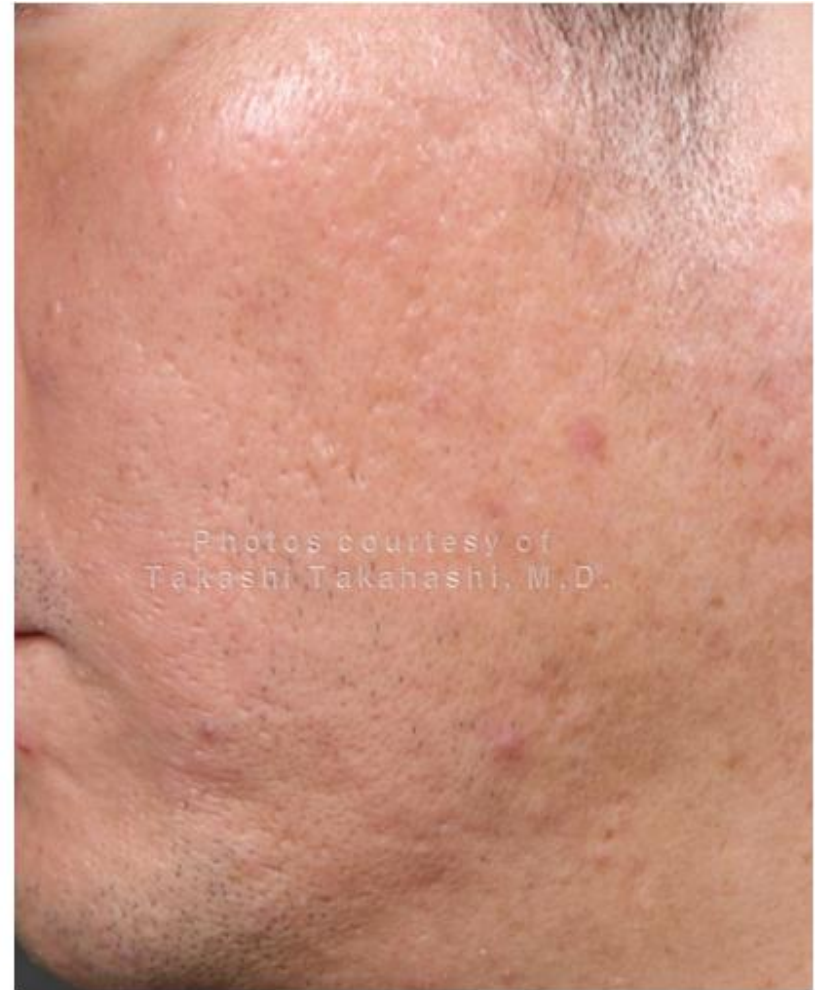3<sup>rd</sup> treatment 04/28/2009

4<sup>th</sup> treatment 06/04/2009

Full face : Bipolar Level 3 - 0.8/1.5mm, 1/2 overlap



**Before Treatment**



**Before 4<sup>th</sup> Treatment**

# Scar

**Dr. Hyeong-mun Kim**

*MIAERO Clinic, Seoul, Korea*

# INTRAcel

**38, Male**

1<sup>st</sup> treatment 02/10/2009

2<sup>nd</sup> treatment 03/12/2009

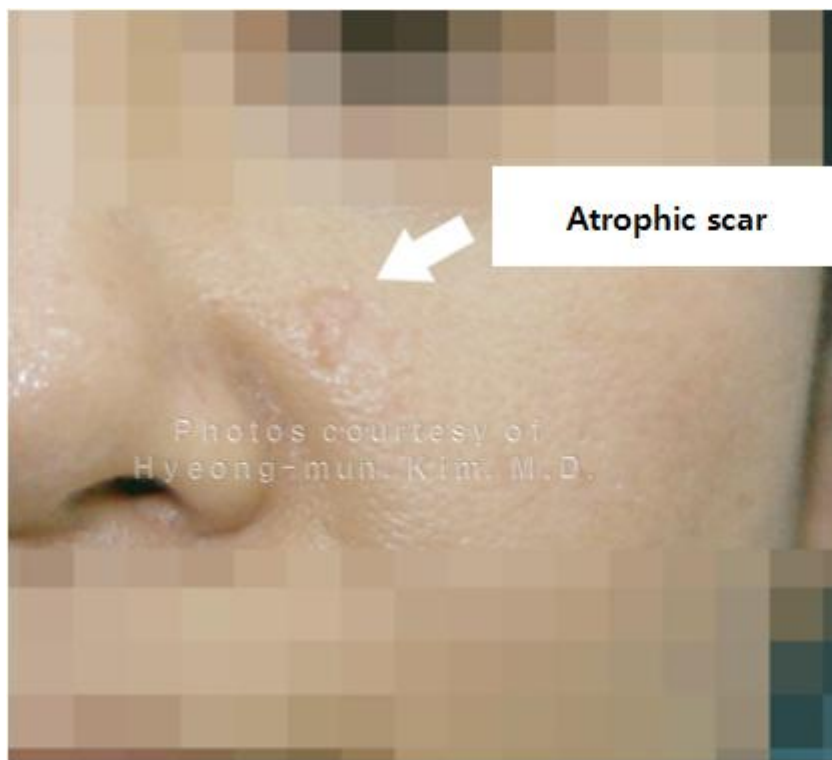
3<sup>rd</sup> treatment 04/28/2009

4<sup>th</sup> treatment 06/04/2009

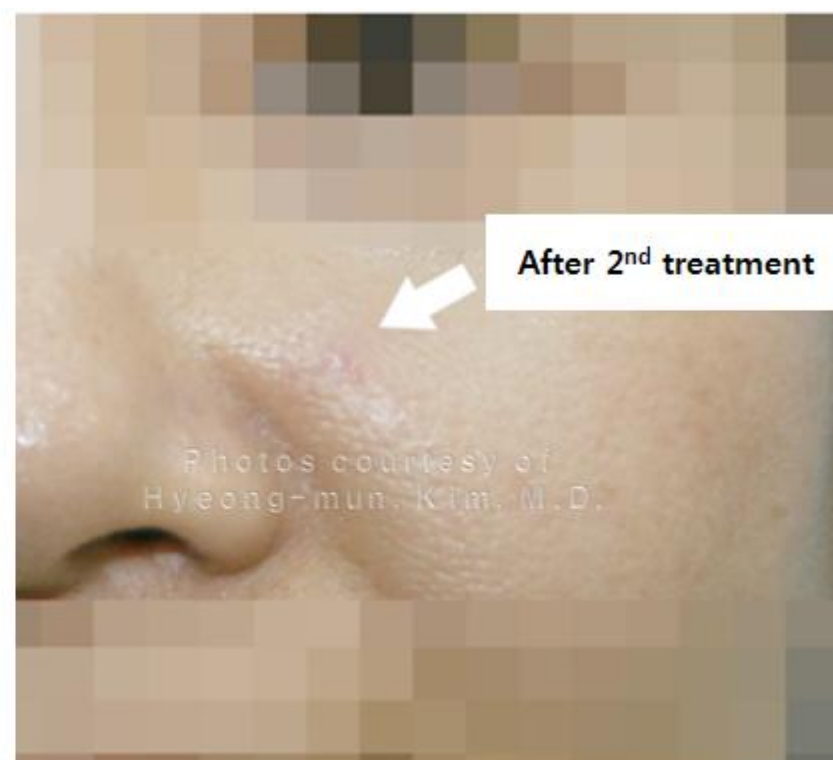Partial treatment : Monopolar Level 5 – 1.5mm, 5-10 multiple shots

Apply EGF for 5 days after 2<sup>nd</sup> treatment

2 treatment with 6 weeks interval



**Before Treatment**



**Before 2<sup>nd</sup> Treatment**

# Scar

**Dr. Takashi Takahashi**

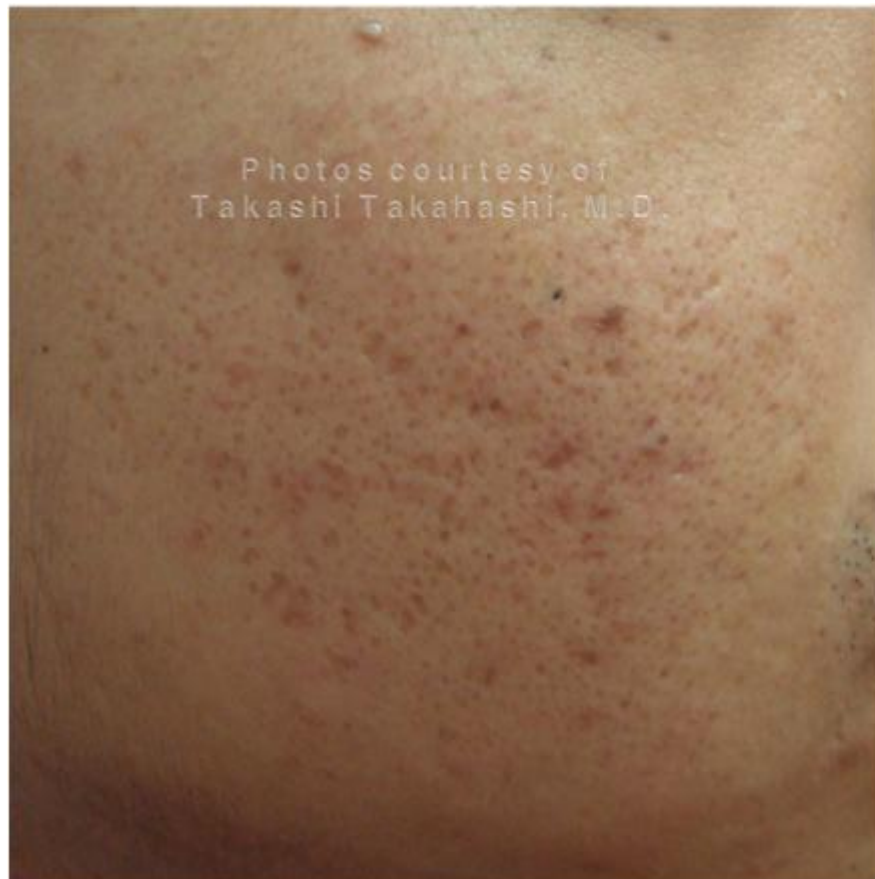*Takashi Takahashi Clinic, Tokyo, JAPAN*

**INTRAcel**

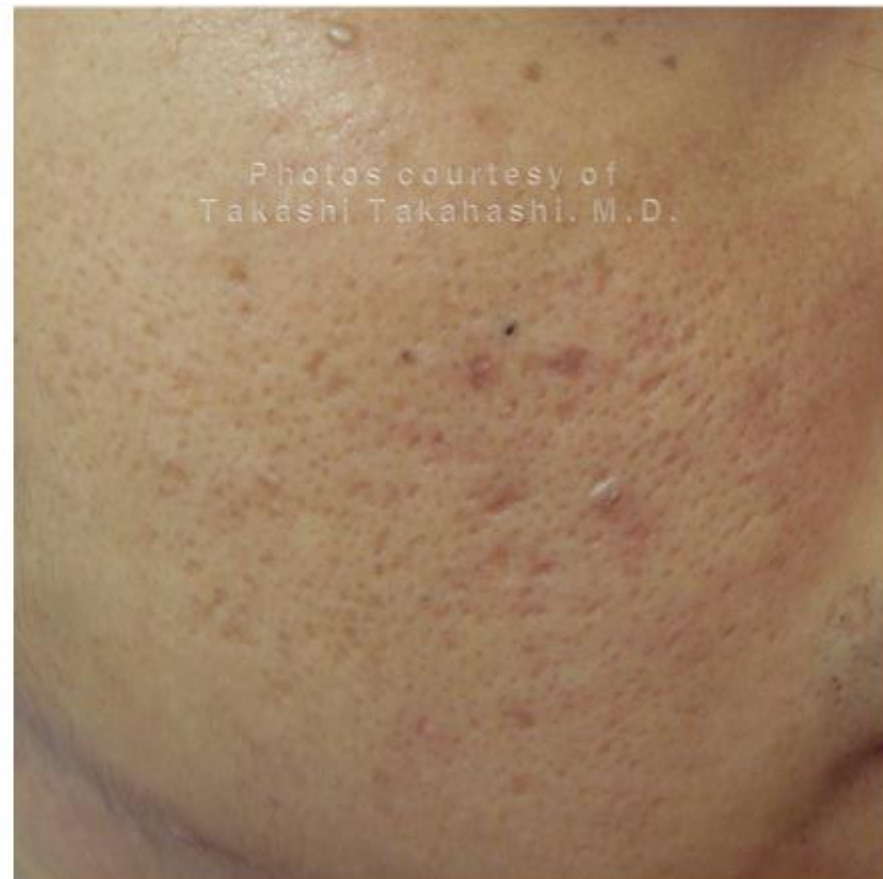**30, Male**

1<sup>st</sup> treatment 05/15/2009

2<sup>nd</sup> treatment 06/16/2009



**Before Treatment**



**Before 2<sup>nd</sup> Treatment**

Scar

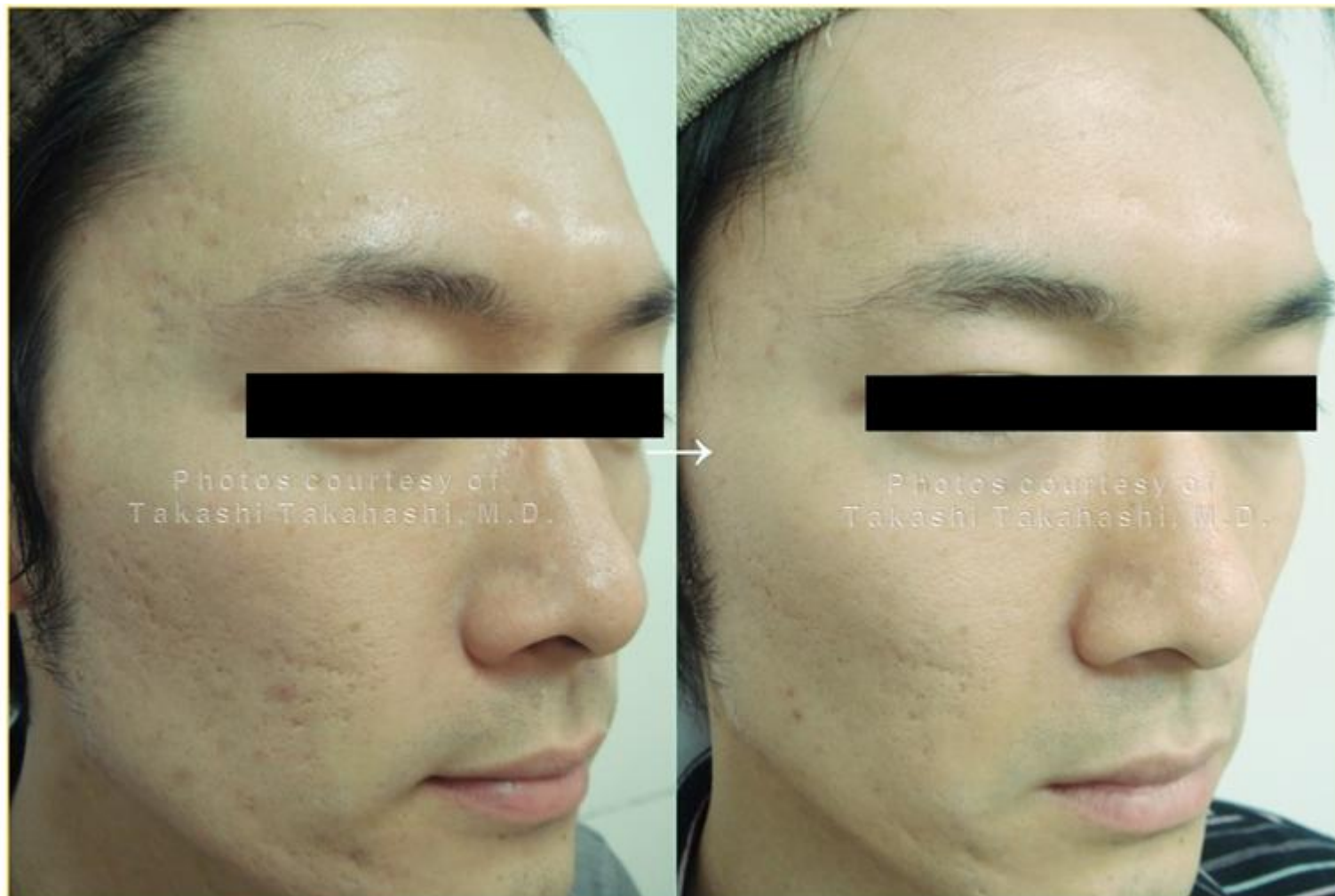**Dr. Takashi Takahashi**

*Takashi Takahashi Clinic, Tokyo, JAPAN*

**INTRAcE**

**28, Male**

Full face : Bipolar Level 4 – 2passes are treated



**Before Treatment**

**45 days after Treatment**

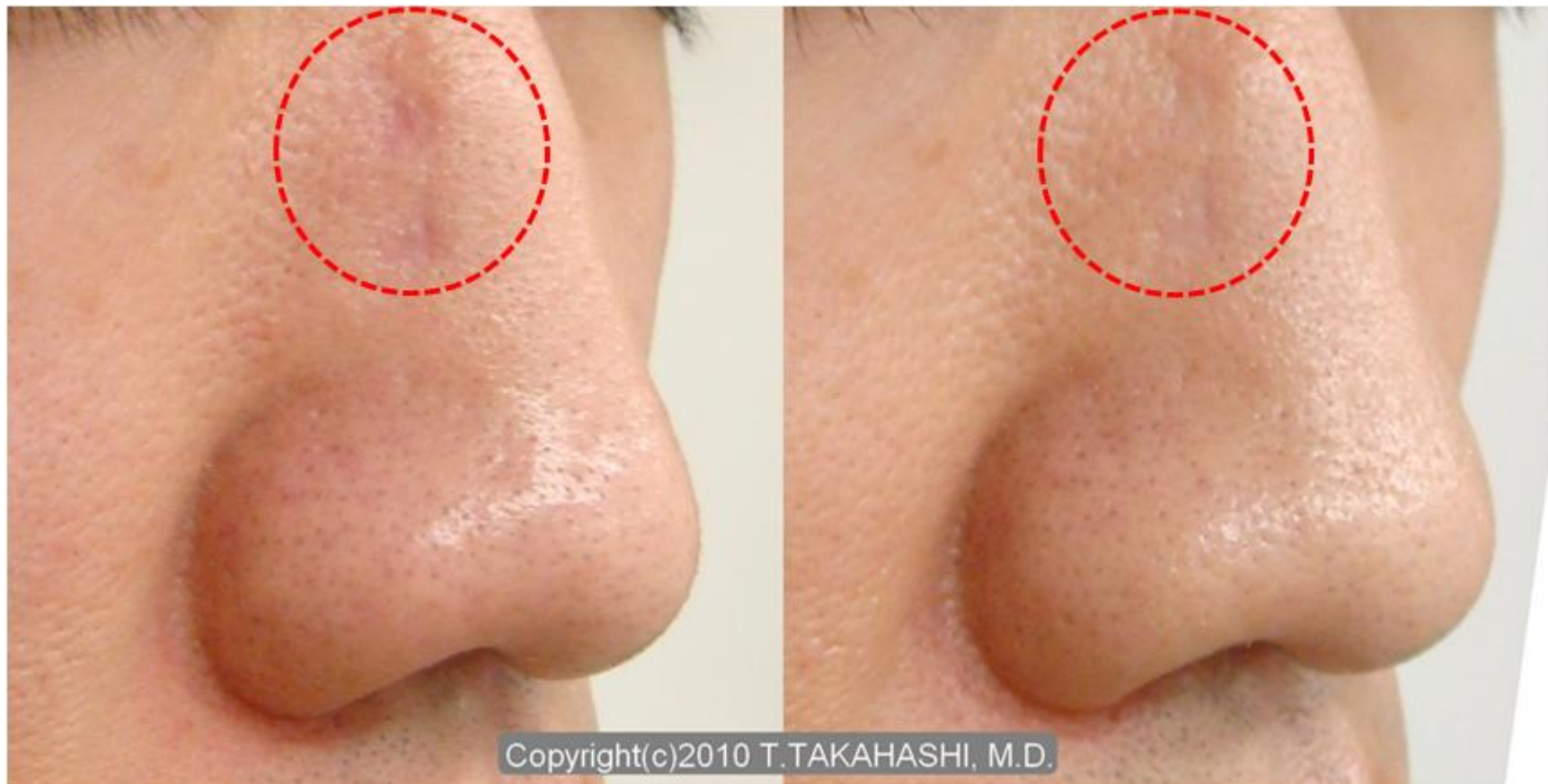Scar

**Dr. Takashi Takahashi**

*Takashi Takahashi Clinic, Tokyo, JAPAN*

**INTRAcel**

**19, Male**



**Before Treatment**

**42 days after Treatment**

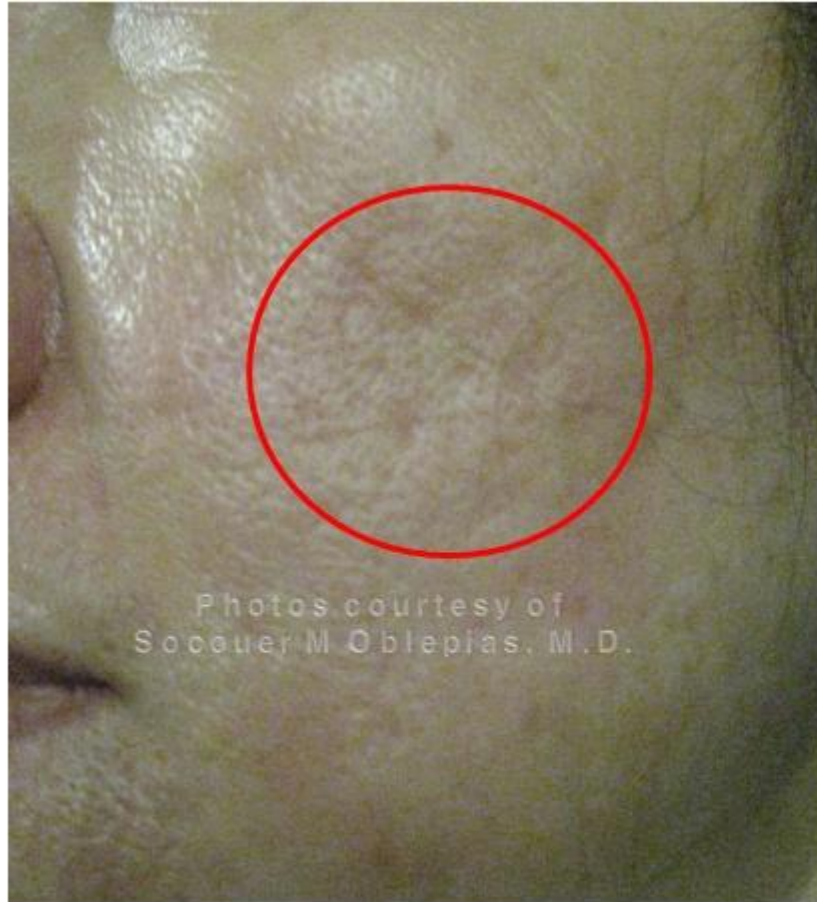# Scar

**Dr. Socouer M. Oblepias**

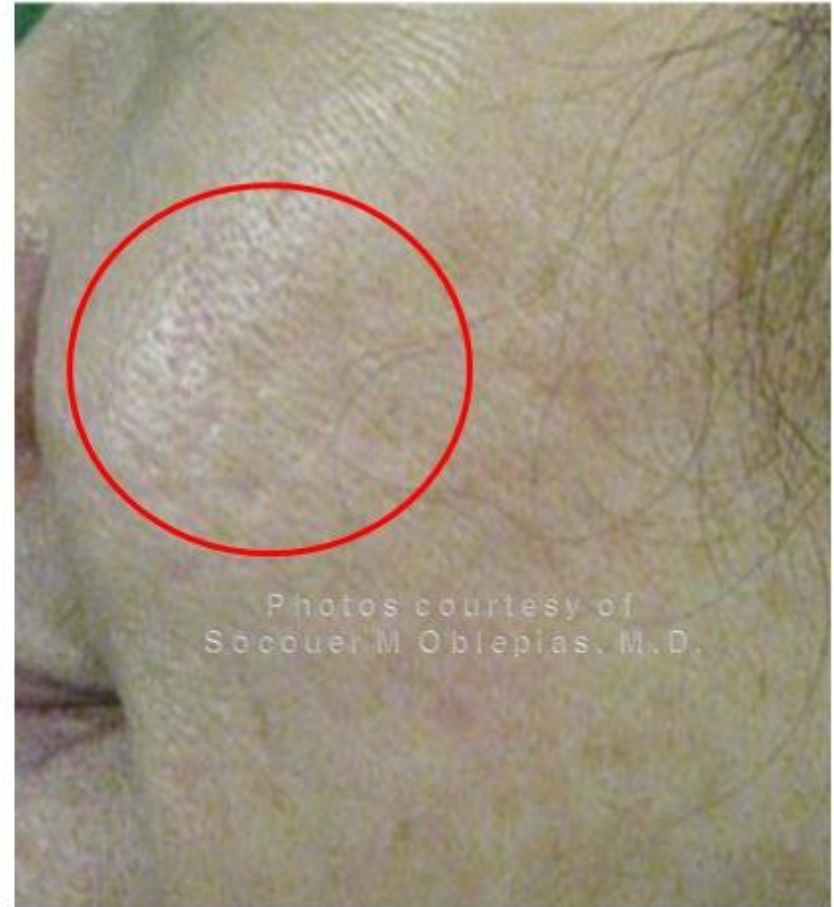*Acnecure Center, Manila, Philippines*

**INTRAcel**

**Female**



**Before Treatment**



**4 weeks after 2<sup>nd</sup> Treatment**

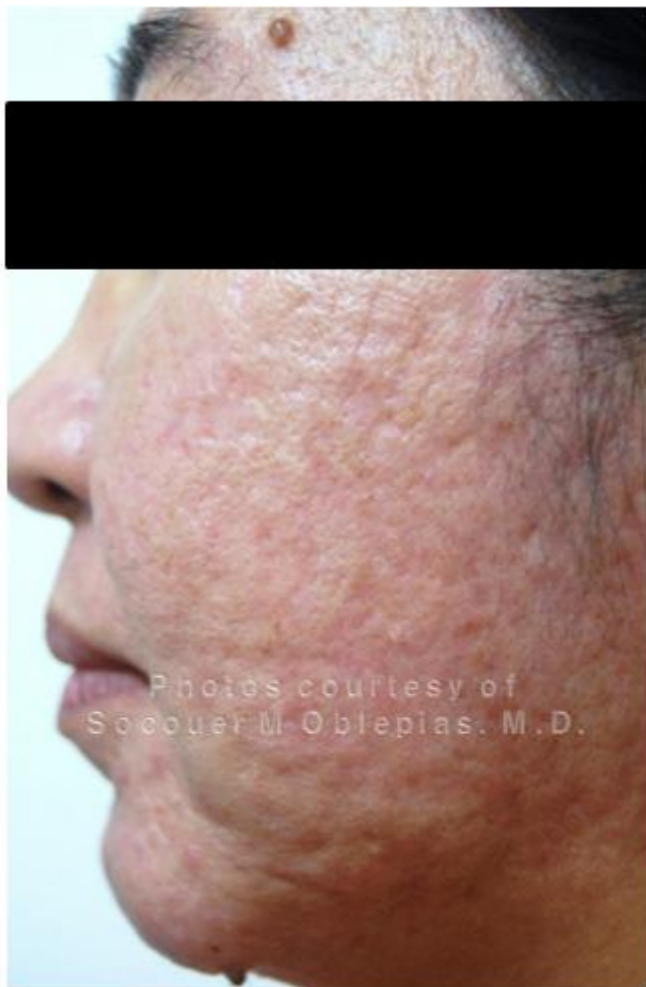# Scar

**Dr. Socouer M. Oblepias**

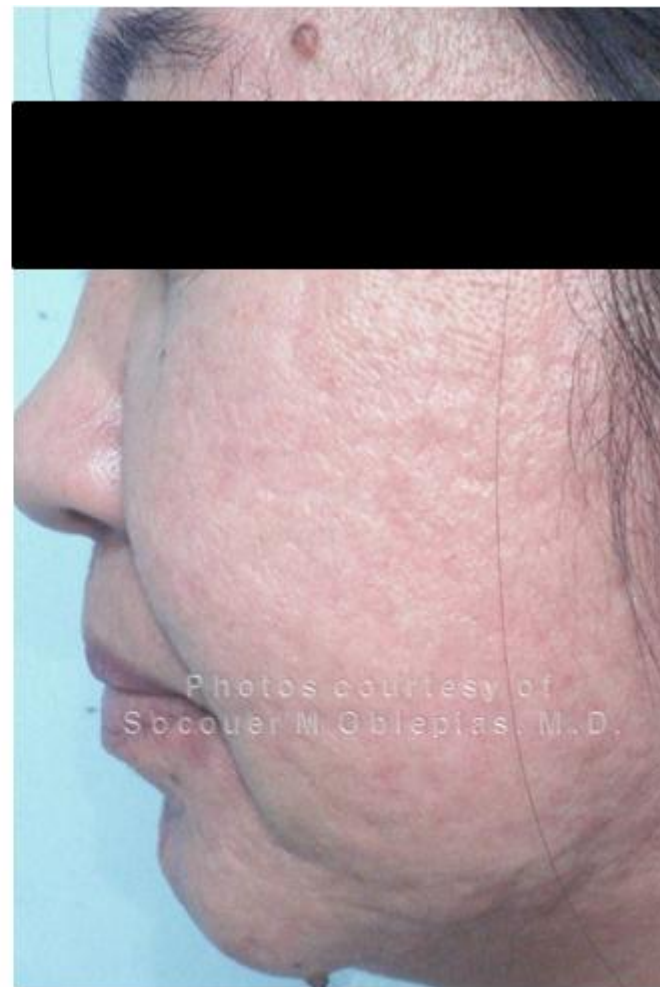*Acnecure Center, Manila, Philippines*

**INTRAcel**

**Female**



**Before Treatment**



**4 weeks after 2<sup>nd</sup> Treatment**

# Clinical result of INTRAcel

**Large pore**



# Large pore

**Dr. Takashi Takahashi**

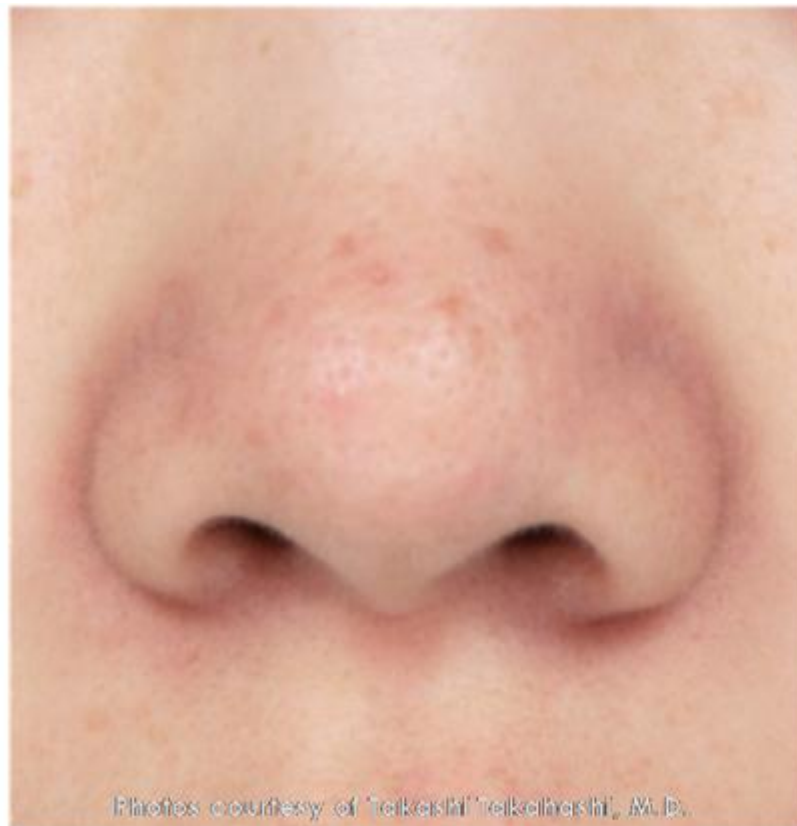
*Takashi Takahashi Clinic, Tokyo, JAPAN*

**INTRAcel**

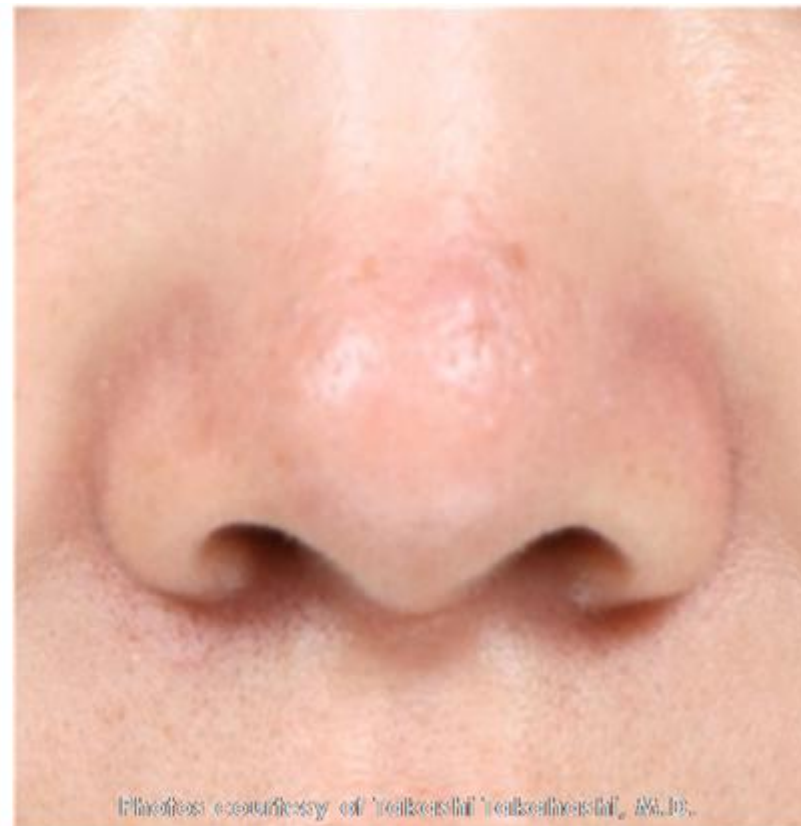**28, Female**

1<sup>st</sup> treatment 11/08/2008

2<sup>nd</sup> treatment 12/06/2008



**Before Treatment**



**Before 2<sup>nd</sup> Treatment**

# Large pore

**Dr. Takashi Takahashi**

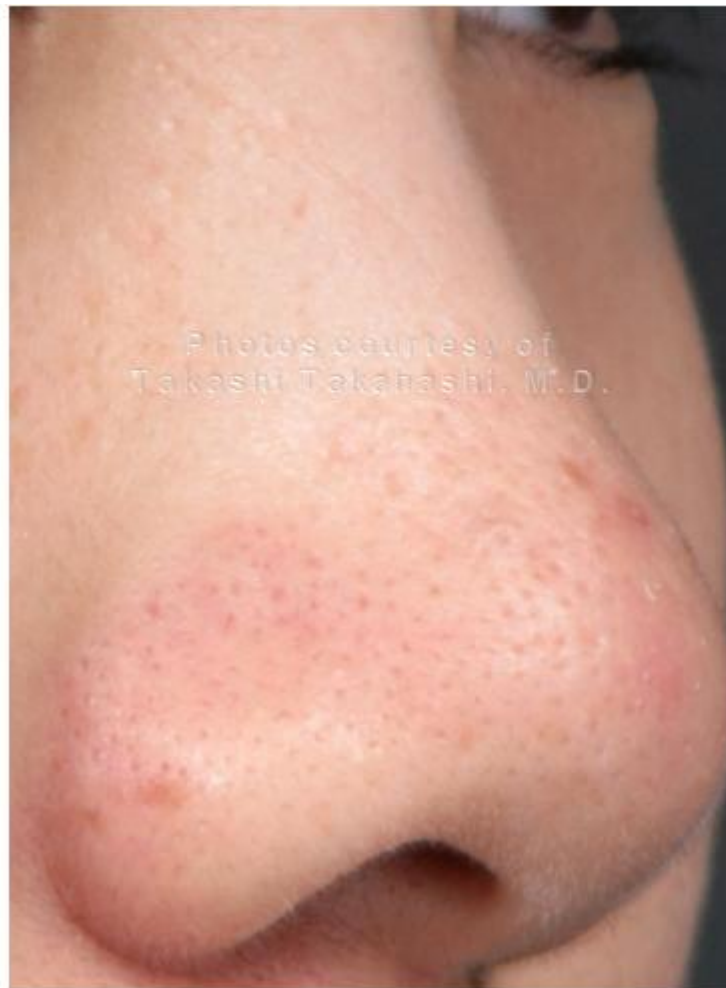*Takashi Takahashi Clinic, Tokyo, JAPAN*

# **INTRAcnel**

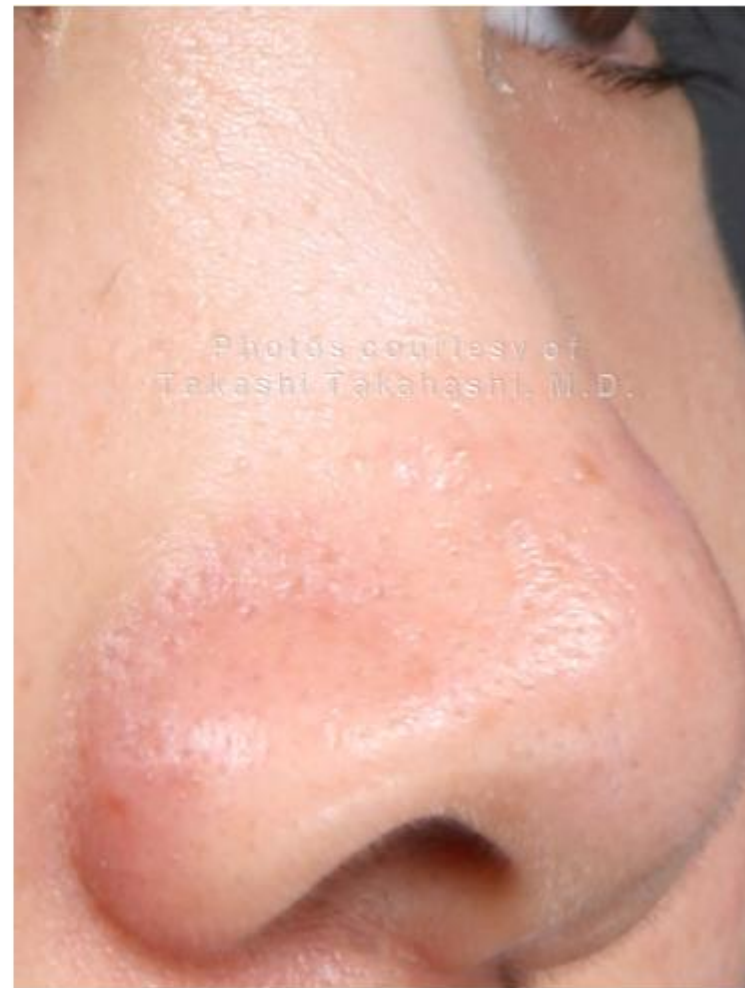**28, Female**

1<sup>st</sup> treatment 11/08/2008

2<sup>nd</sup> treatment 12/06/2008



**Before Treatment**



**Before 2<sup>nd</sup> Treatment**

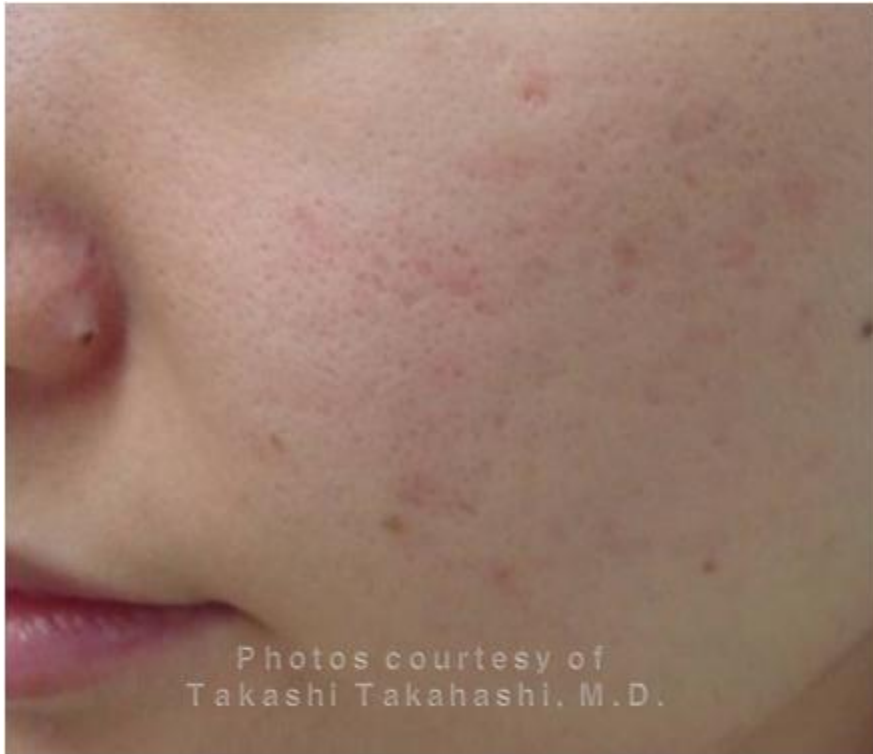## Large pore

**Dr. Takashi Takahashi**

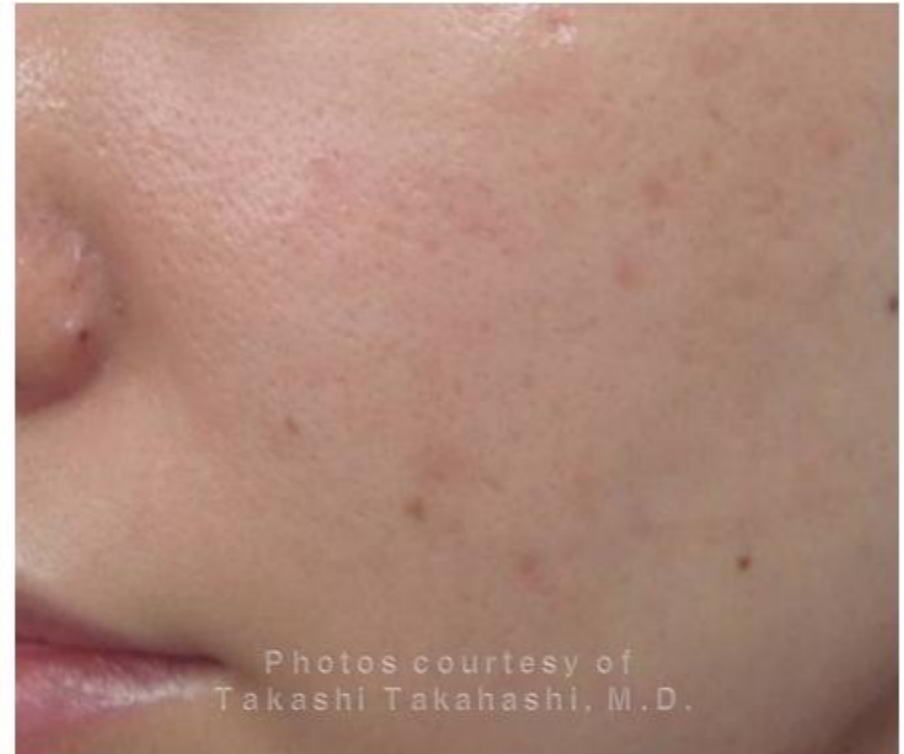*Takashi Takahashi Clinic, Tokyo, JAPAN*

**30, Female**

Full face : Bipolar Level 4 – 2passes are treated



**Before Treatment**



**1 months after Treatment**

# Clinical result of INTRAcel

## Acne scar

# Acne scar

**Dr. Takashi Takahashi**

*Takashi Takahashi Clinic, Tokyo, JAPAN*

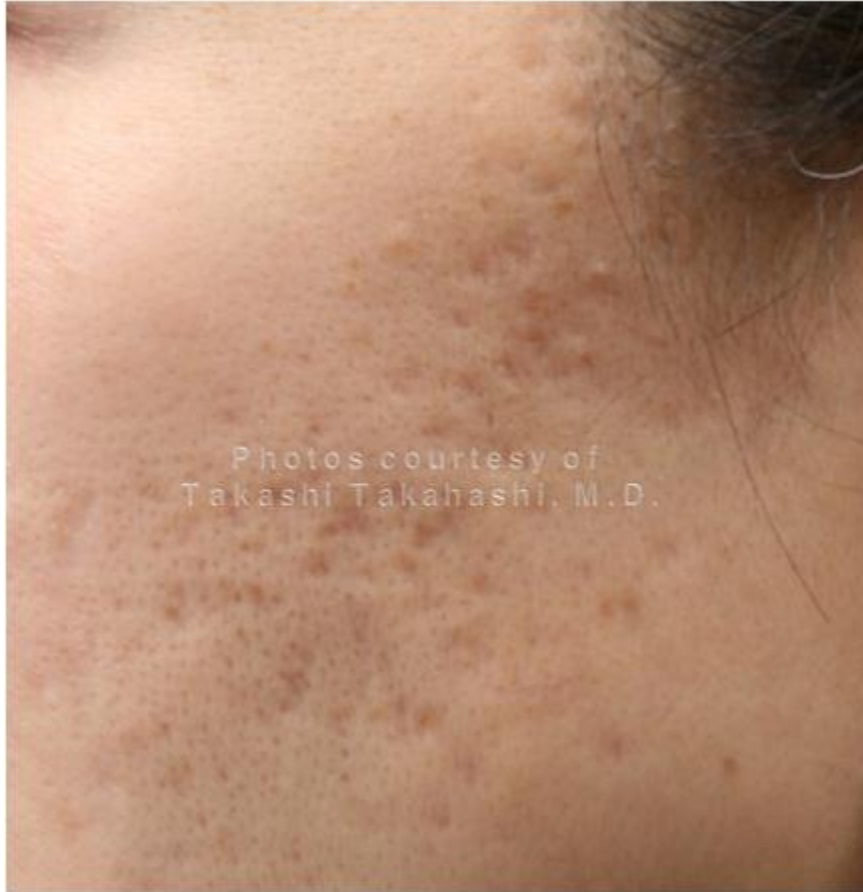# INTRAcel

**37, Female**

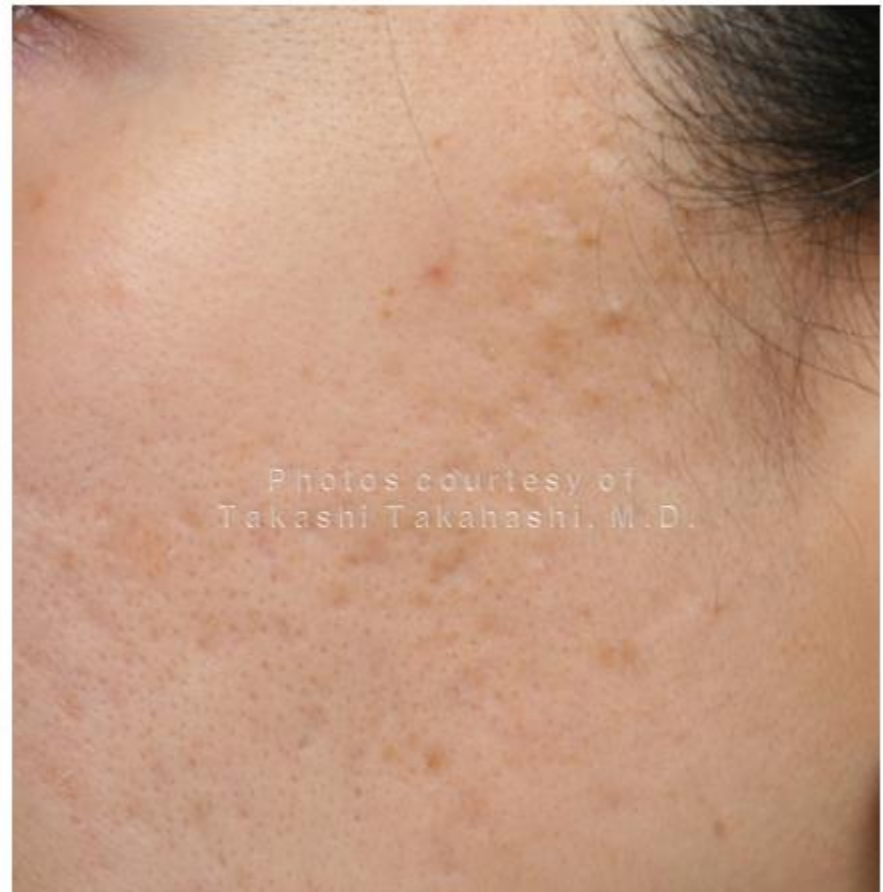
1<sup>st</sup> treatment 01/09/2009

2<sup>nd</sup> treatment 02/20/2009

Full face : Bipolar Level 2 – 1.5mm, 2-3pass



**Before Treatment**



**42days after 1<sup>st</sup> Treatment**

# Acne scar

**Dr. Takashi Takahashi**

*Takashi Takahashi Clinic, Tokyo, JAPAN*

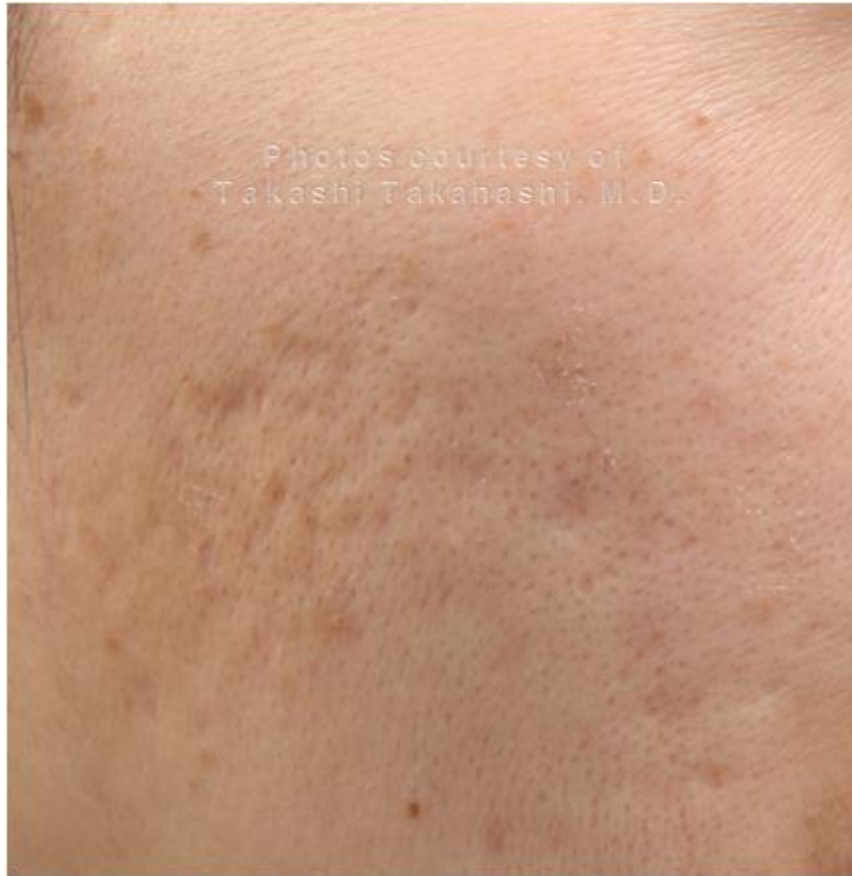**INTRAcE**

**37, Female**

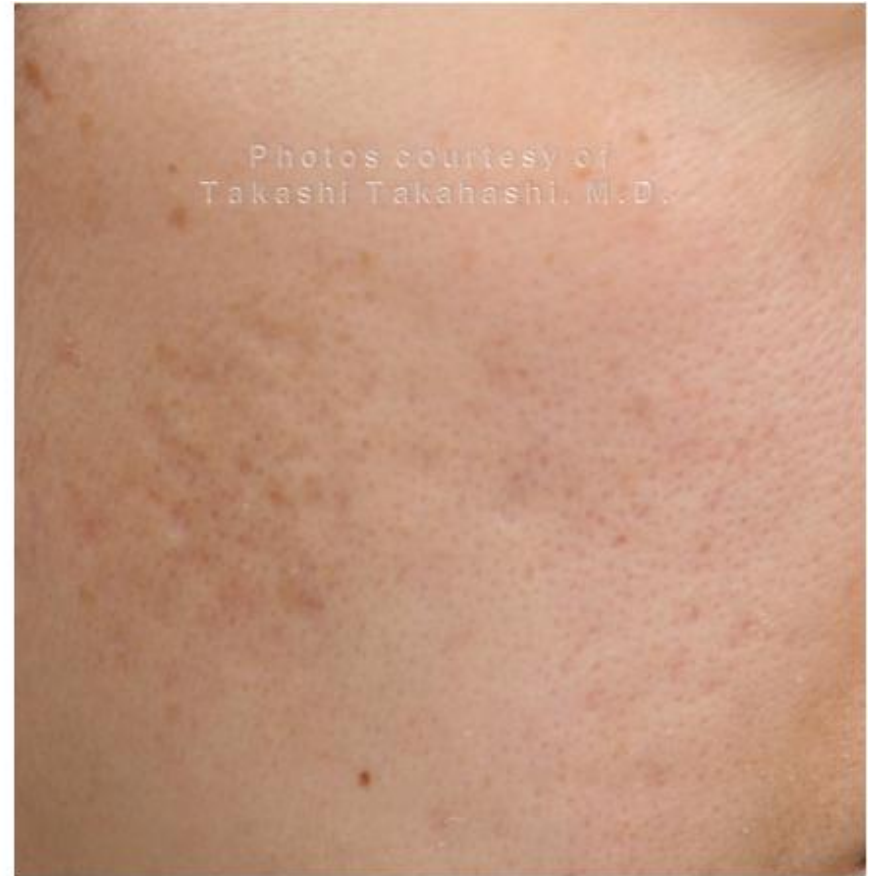
1<sup>st</sup> treatment 01/09/2009

2<sup>nd</sup> treatment 02/20/2009

Full face : Bipolar Level 2 – 1.5mm, 2-3pass



**Before Treatment**



**42days after 1<sup>st</sup> Treatment**

# Acne scar

**Dr. Takashi Takahashi**

*Takashi Takahashi Clinic, Tokyo, JAPAN*

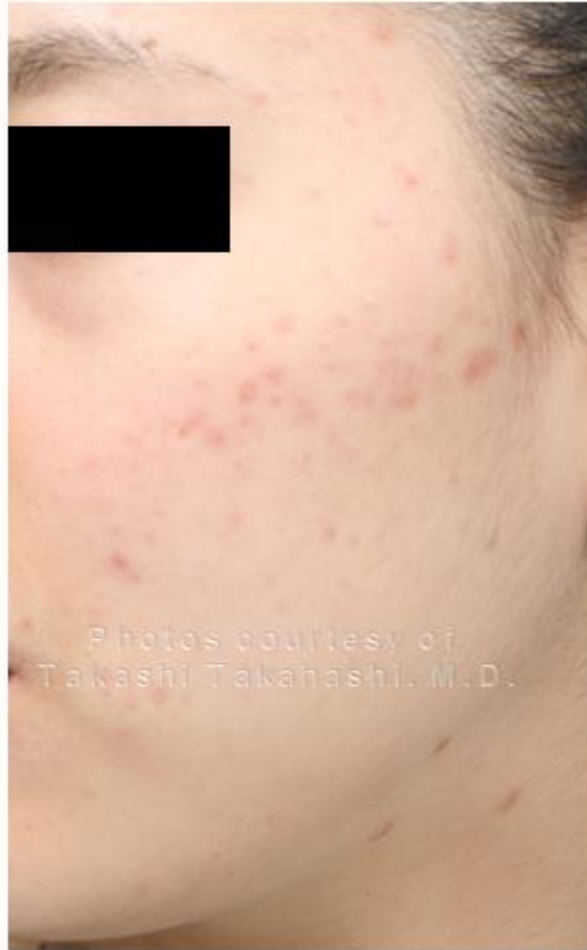# INTRAcel

**22, Female**

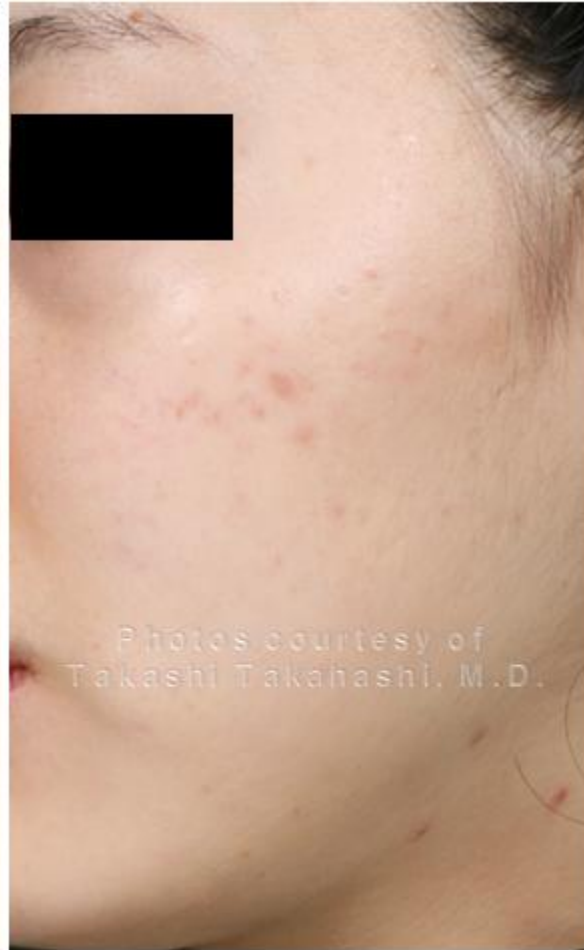1<sup>st</sup> treatment 01/14/2009

2<sup>nd</sup> treatment 02/19/2009

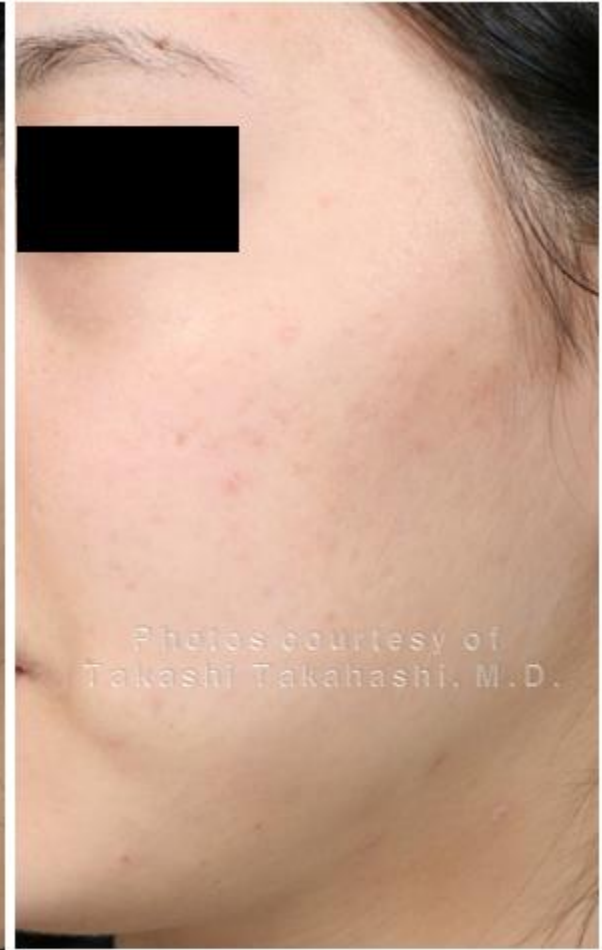3<sup>rd</sup> treatment 04/06/2009



**Before  
Treatment**



**35 days after  
1<sup>st</sup> Treatment**



**46 days after  
2<sup>nd</sup> Treatment**

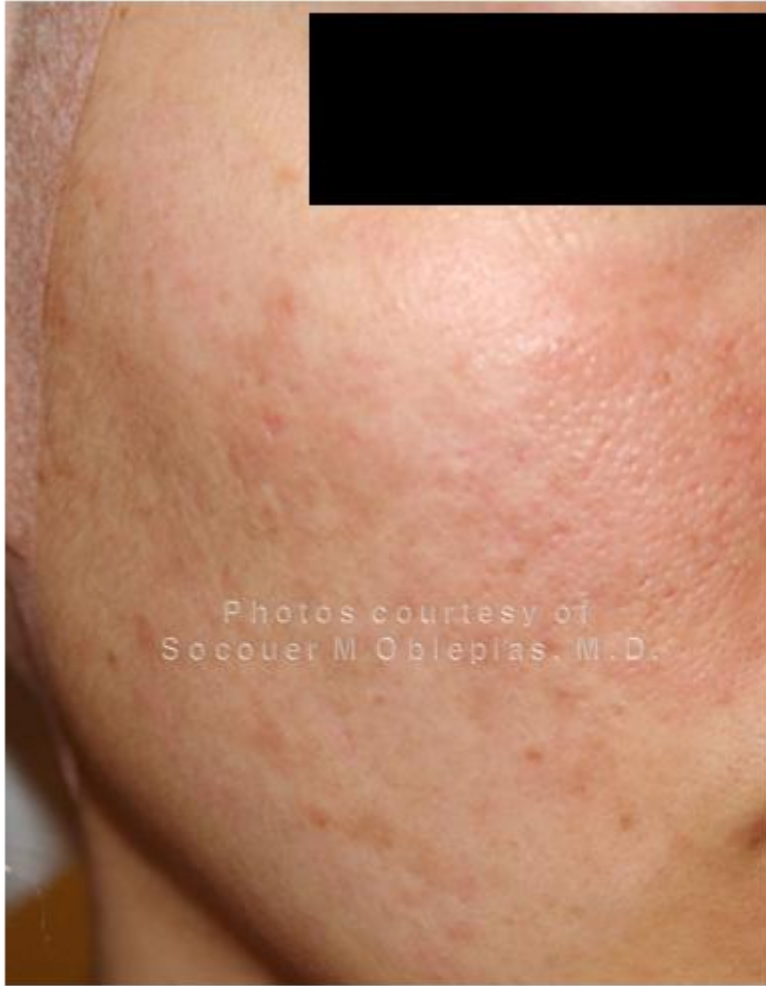# Acne scar

**Dr. Socouer M. Oblepias**

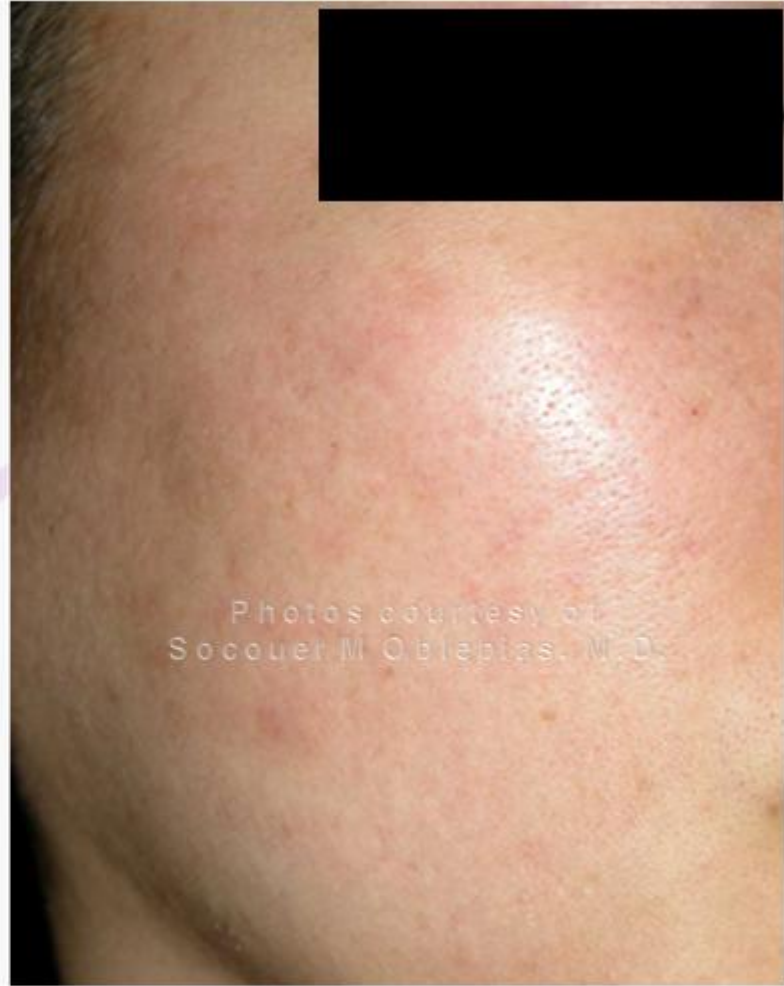*Acnecure Center, Manila, Philippines*

**INTRAcel**

**Female**



**Before Treatment**



**After 3<sup>rd</sup> Treatment**



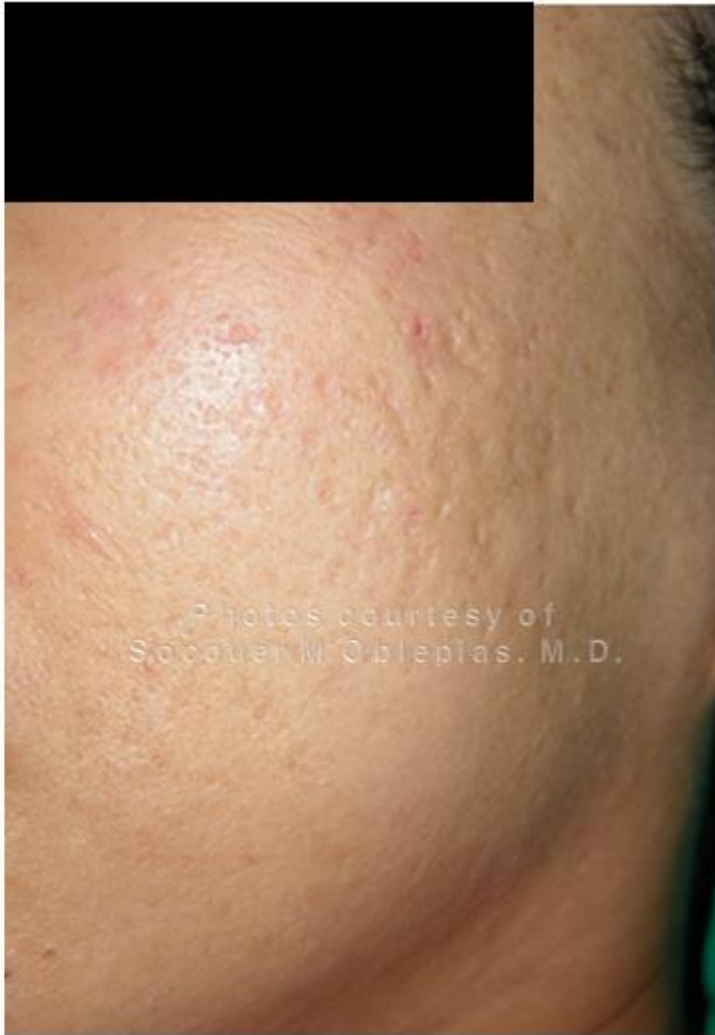# Acne scar

**Dr. Socouer M. Oblepias**

*Acnecure Center, Manila, Philippines*

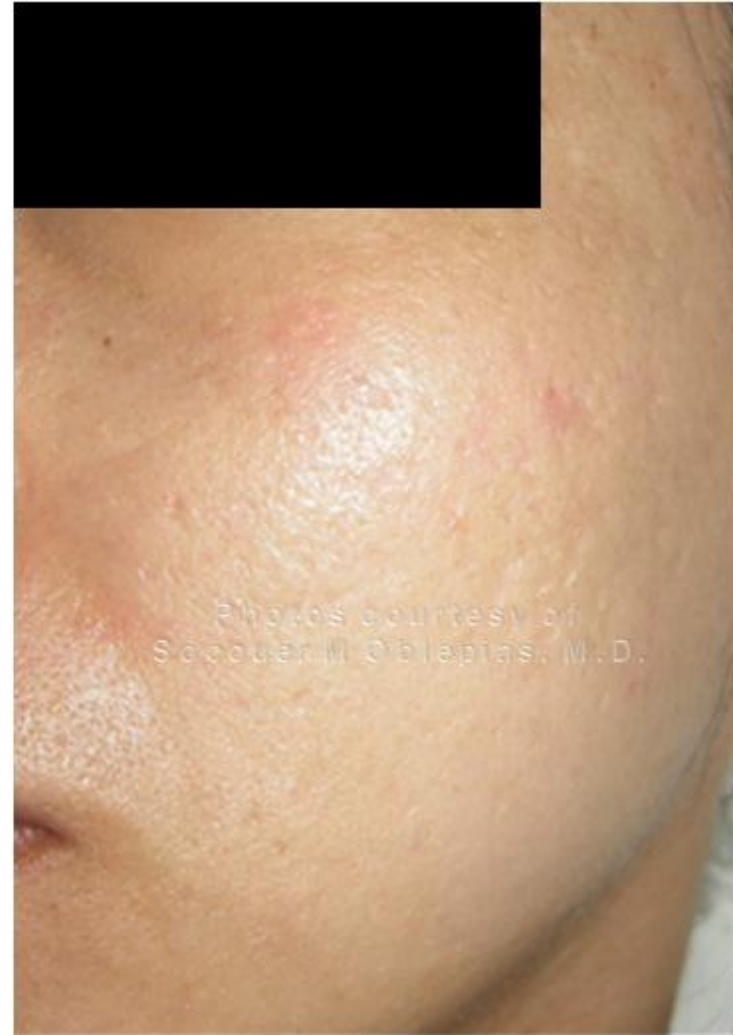**INTRAcE**

**Female**



Photos courtesy of  
Socouer M. Oblepias, M.D.

**Before Treatment**



Photos courtesy of  
Socouer M. Oblepias, M.D.

**After 4<sup>th</sup> Treatment**

# Clinical result of INTRAcel

# Acne

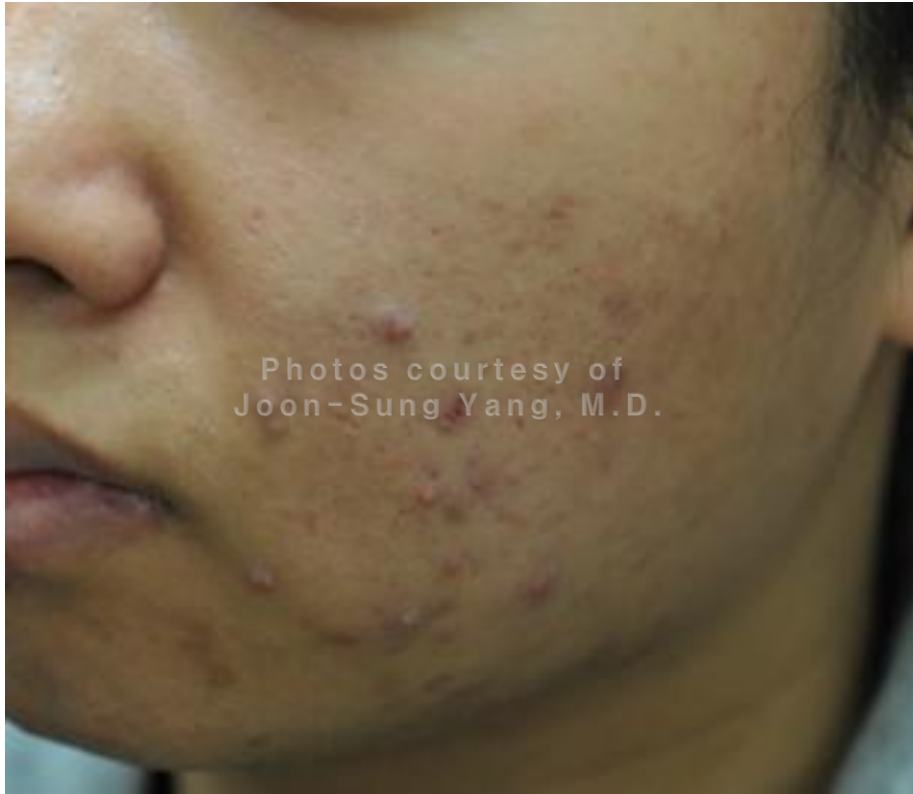# Acne

## Dr. Joon-Sung Yang

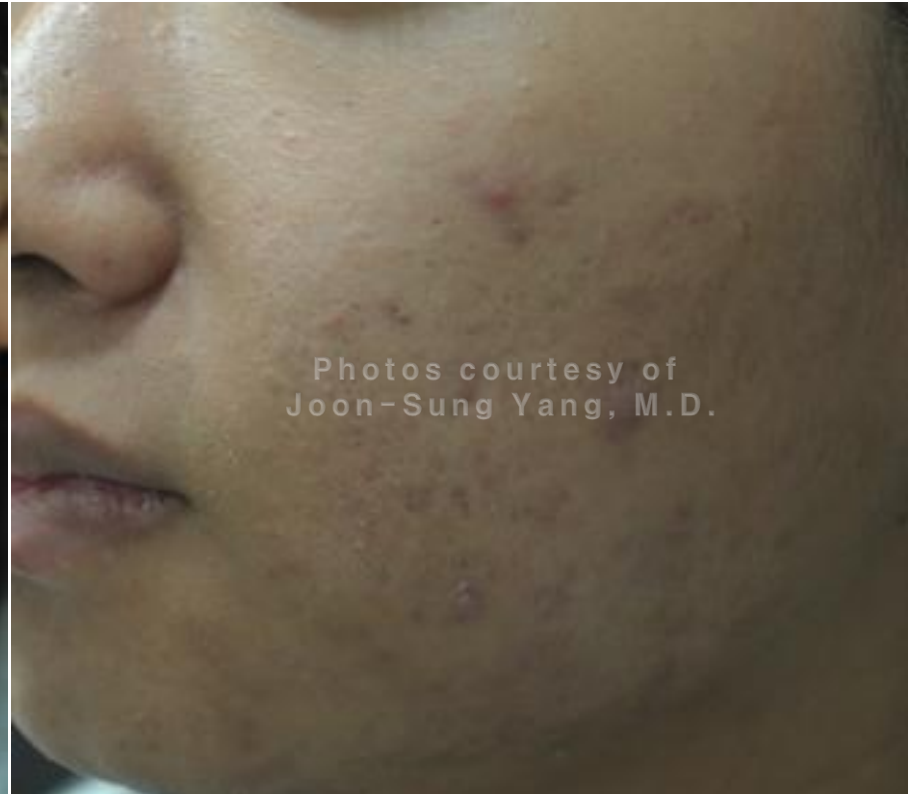*Aroomdawoon Dermatologic Clinic, Jeju, KOREA*

# INTRAcel

Male



**Before Treatment**



**1 month after Treatment**

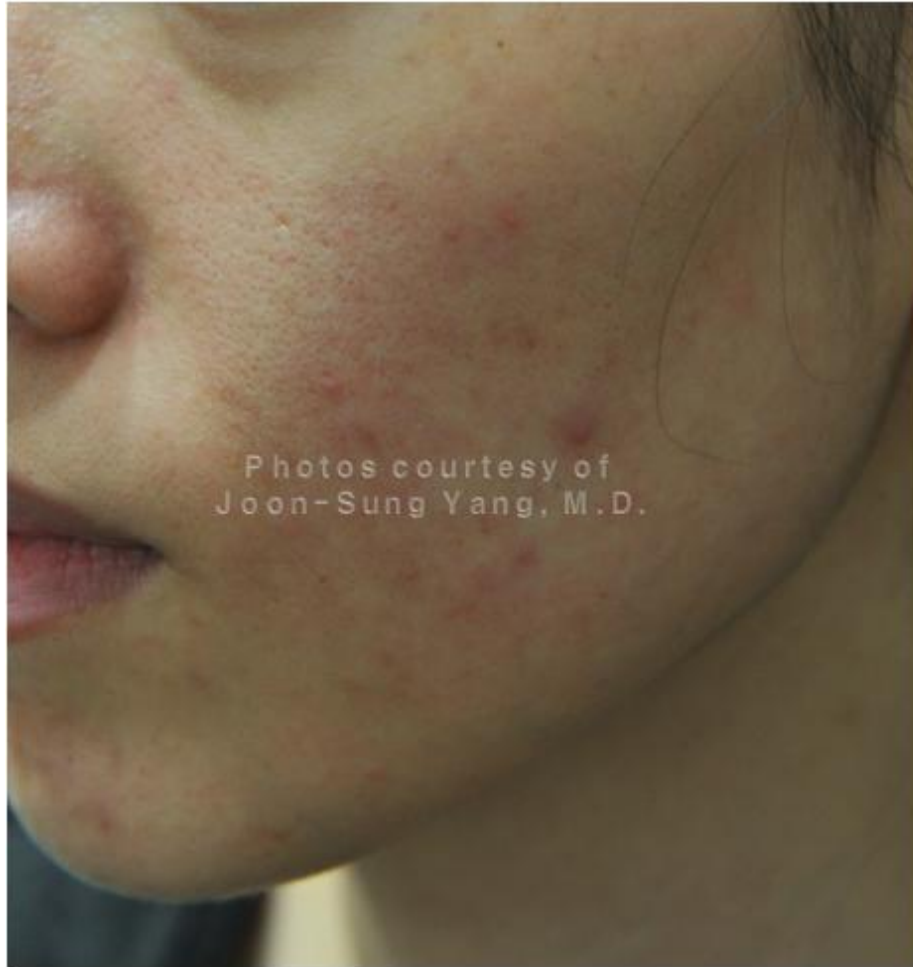# Acne

**Dr. Joon-Sung Yang**

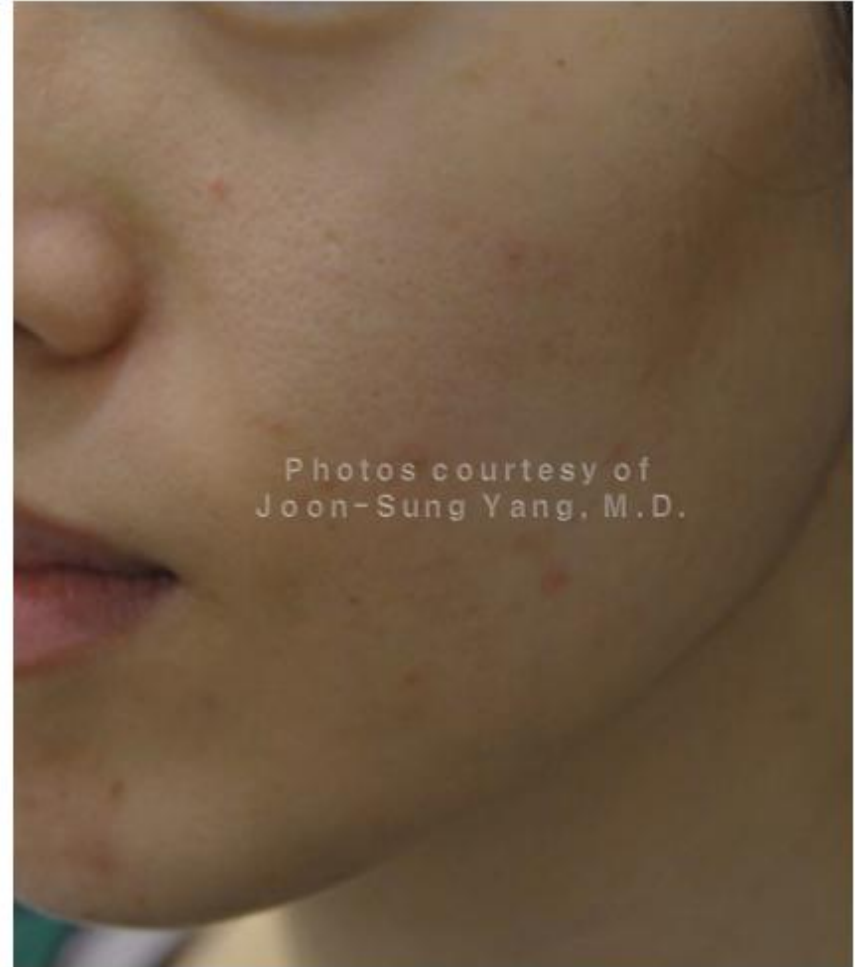
*Aroomdawoon Dermatologic Clinic, Jeju, KOREA*

**INTRAcel**

**Female**



Photos courtesy of  
Joon-Sung Yang, M.D.



Photos courtesy of  
Joon-Sung Yang, M.D.

**Before Treatment**

**after 2<sup>nd</sup> Treatment**

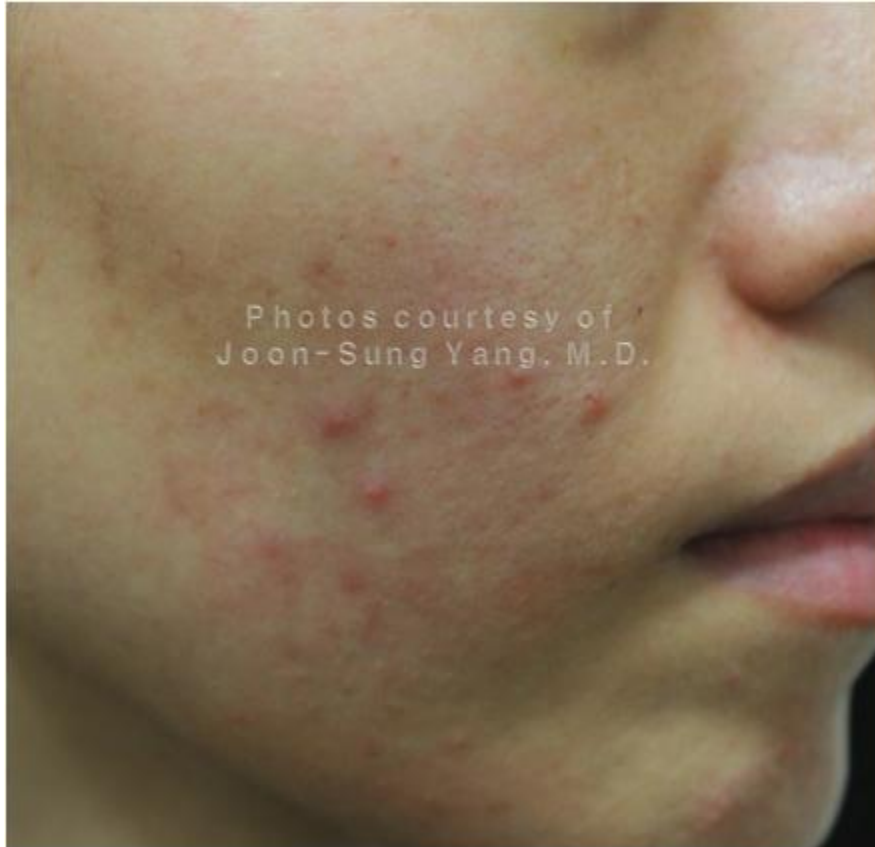# Acne

**Dr. Joon-Sung Yang**

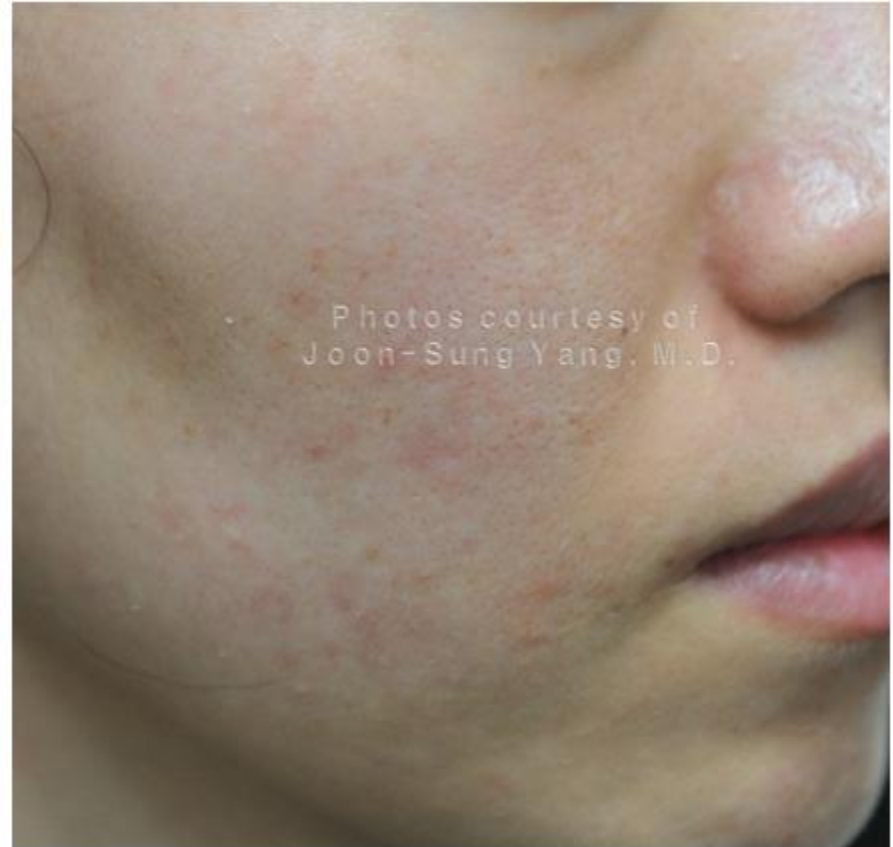*Aroomdawoon Dermatologic Clinic, Jeju, KOREA*

**INTRAcel**

**Female**



**Before Treatment**



**After 1<sup>st</sup> Treatment**

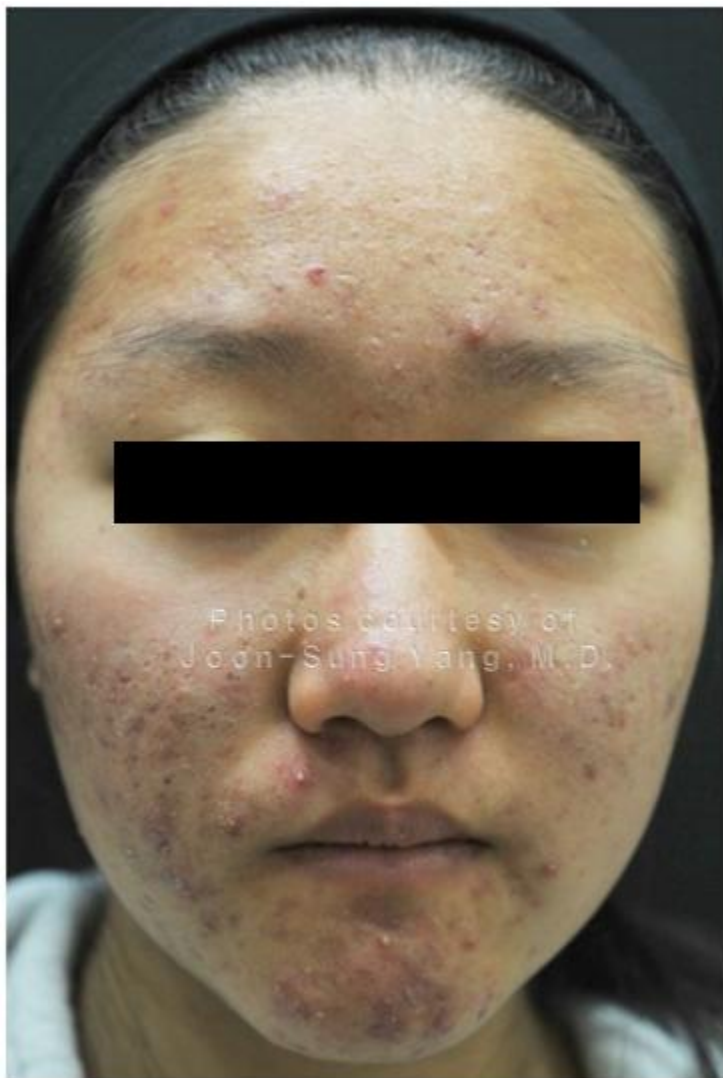
# Acne

**Dr. Joon-Sung Yang**

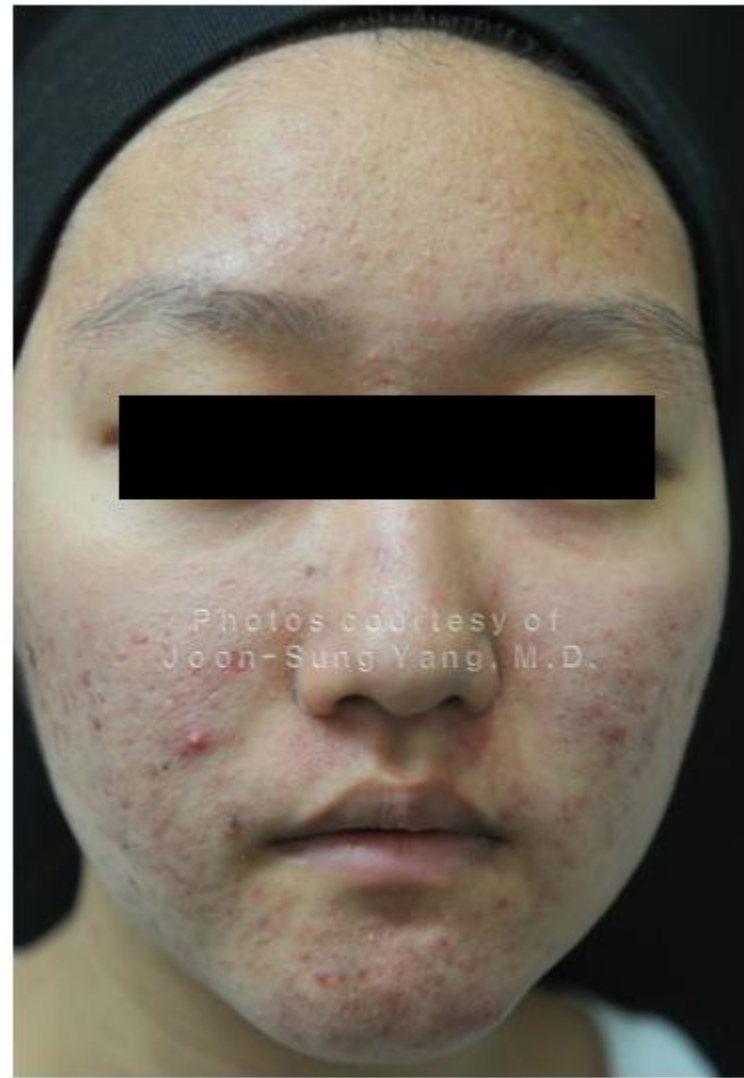*Aroomdawoon Dermatologic Clinic, Jeju, KOREA*

**INTRAcnel**

**Female**



**Before Treatment**



**After 3<sup>rd</sup> Treatment**

**Jeisys**

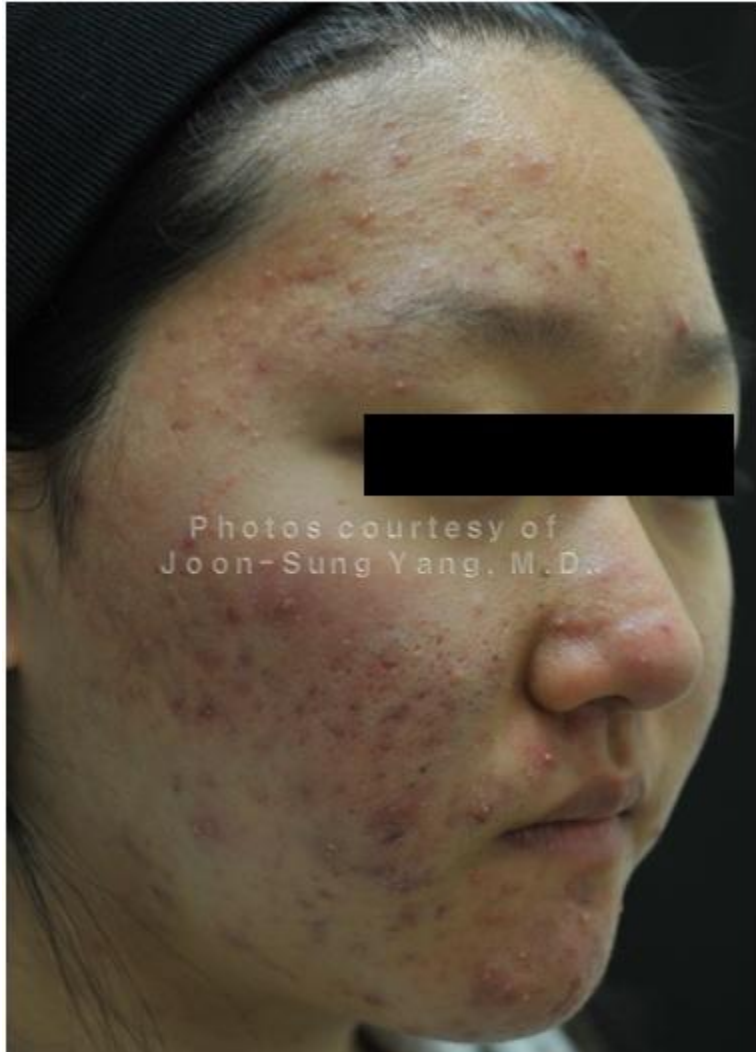# Acne

**Dr. Joon-Sung Yang**

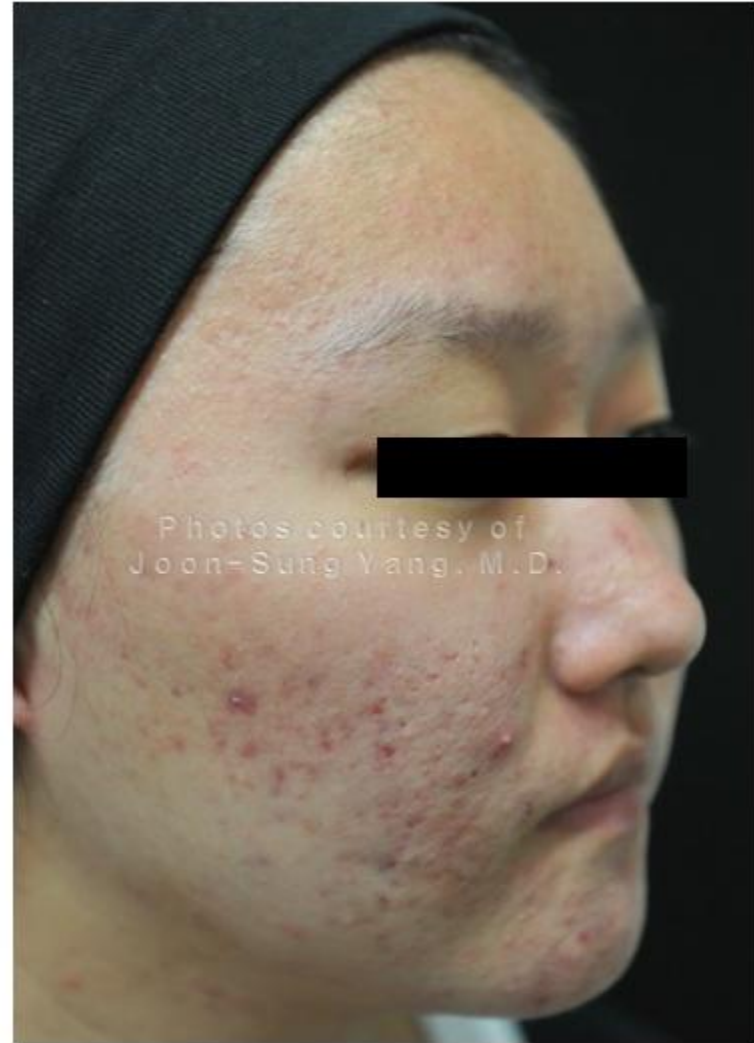*Aroomdawoon Dermatologic Clinic, Jeju, KOREA*

**INTRAcnel**

**Female**



**Before Treatment**



**After 3<sup>rd</sup> Treatment**

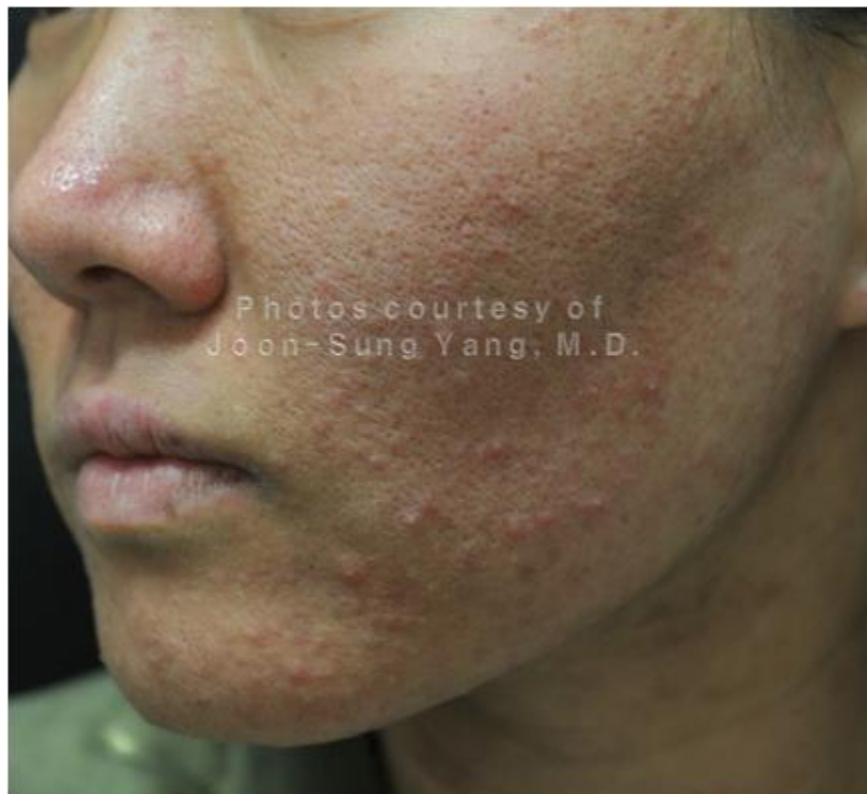# Acne

## Dr. Joon-Sung Yang

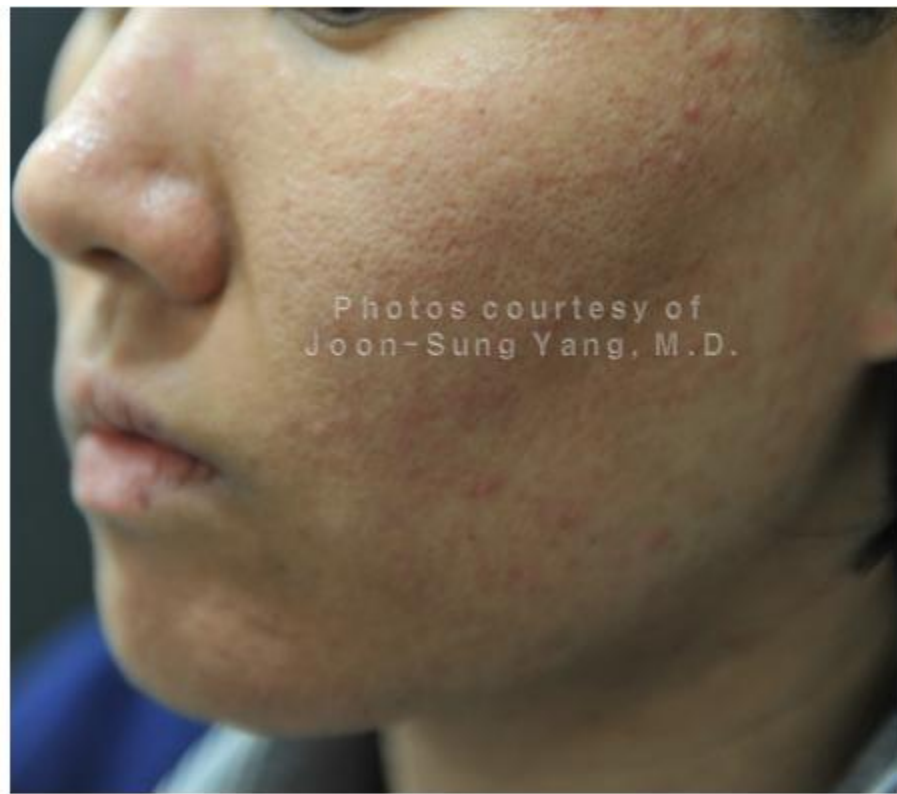*Aroomdawoon Dermatologic Clinic, Jeju, KOREA*

# INTRAcel

Female



Photos courtesy of  
Joon-Sung Yang, M.D.



Photos courtesy of  
Joon-Sung Yang, M.D.

**Before Treatment**

**After 2<sup>nd</sup> Treatment**



## **Clinical result of INTRAcel**

# **Reduction of wrinkles**

# Reduction of wrinkles

## Dr. Takashi Takahashi

*Takashi Takahashi Clinic, Tokyo, JAPAN*

# INTRACel

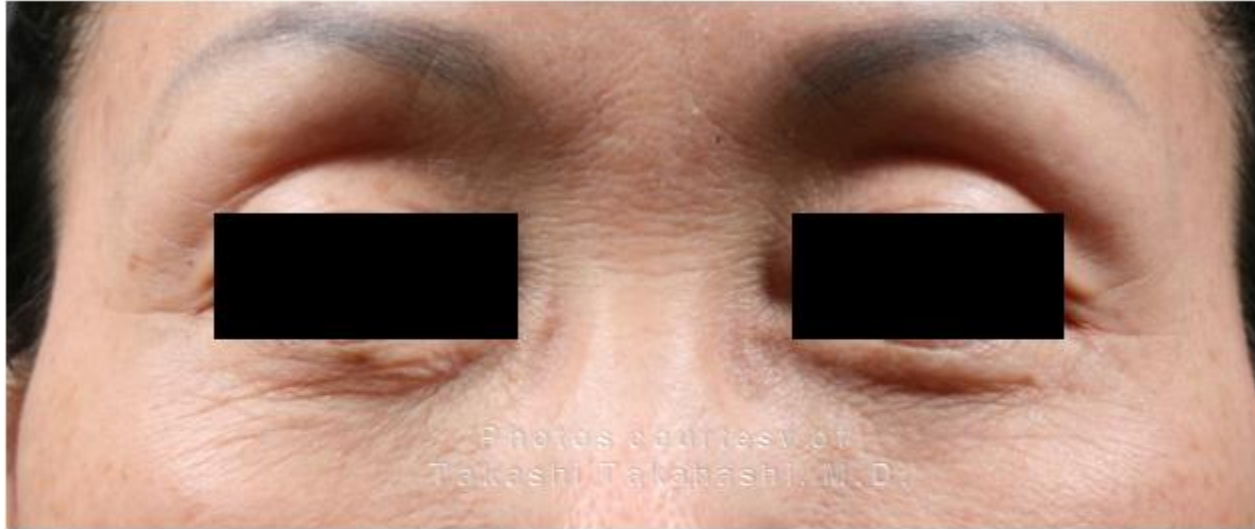**58, Female**

1<sup>st</sup> treatment 01/08/2009

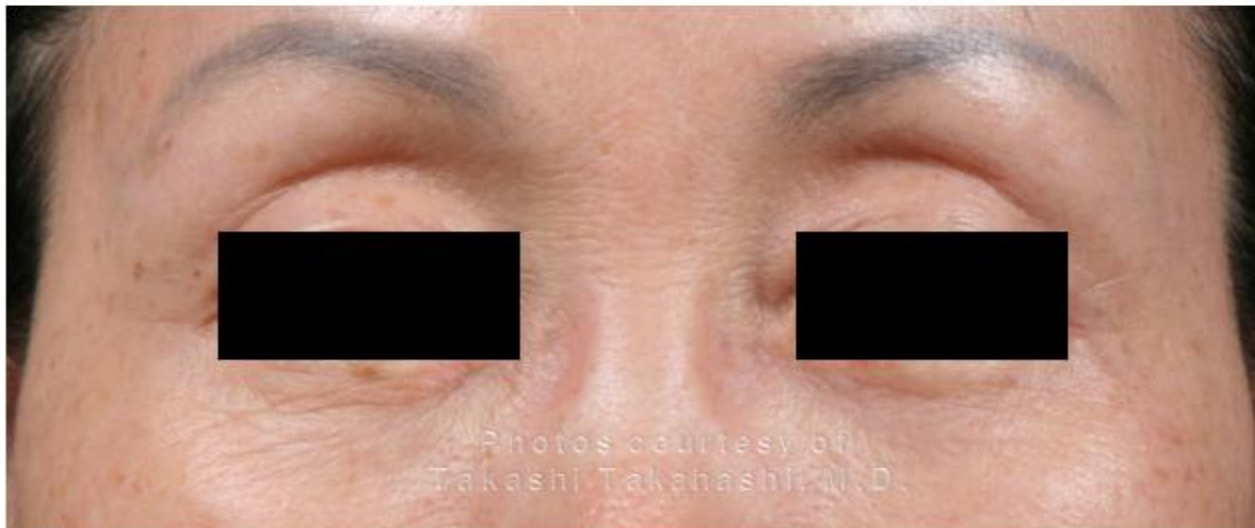2<sup>nd</sup> treatment 03/09/2009

3<sup>rd</sup> treatment 05/15/2009

Full face : Bipolar Level 2 – 1.5mm, 1pass  
Wrinkle : Bipolar Level 2 – 0.8/1.5mm, 2-3pass



**Before Treatment**



**60days after  
1<sup>st</sup> Treatment**

# Reduction of wrinkles

## Dr. Takashi Takahashi

*Takashi Takahashi Clinic, Tokyo, JAPAN*

Full face : Bipolar Level 2 – 1.5mm, 1pass  
Wrinkle : Bipolar Level 2 – 0.8/1.5mm, 2-3pass

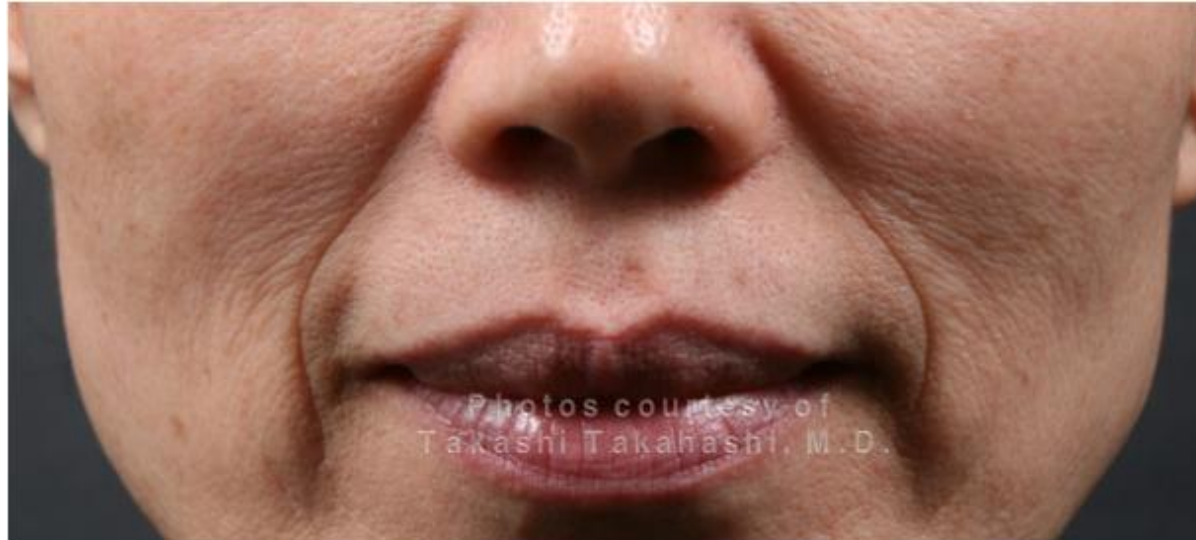# INTRACel

**58, Female**

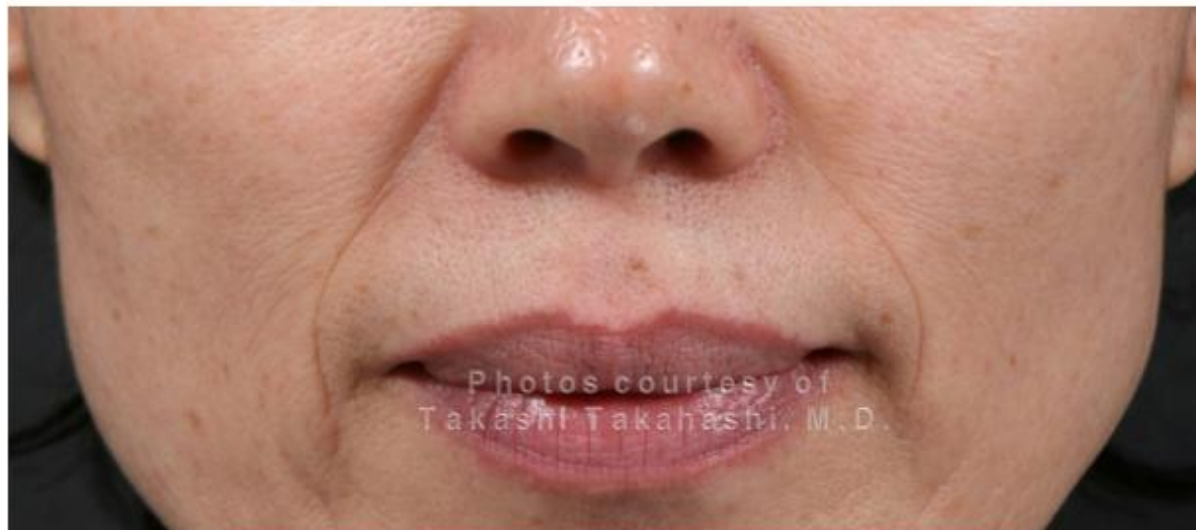1<sup>st</sup> treatment 01/08/2009

2<sup>nd</sup> treatment 03/09/2009

3<sup>rd</sup> treatment 05/15/2009



**Before Treatment**



**60days after  
1<sup>st</sup> Treatment**

# Reduction of wrinkles

## Dr. Takashi Takahashi

*Takashi Takahashi Clinic, Tokyo, JAPAN*

# INTRACel

**38, Male**

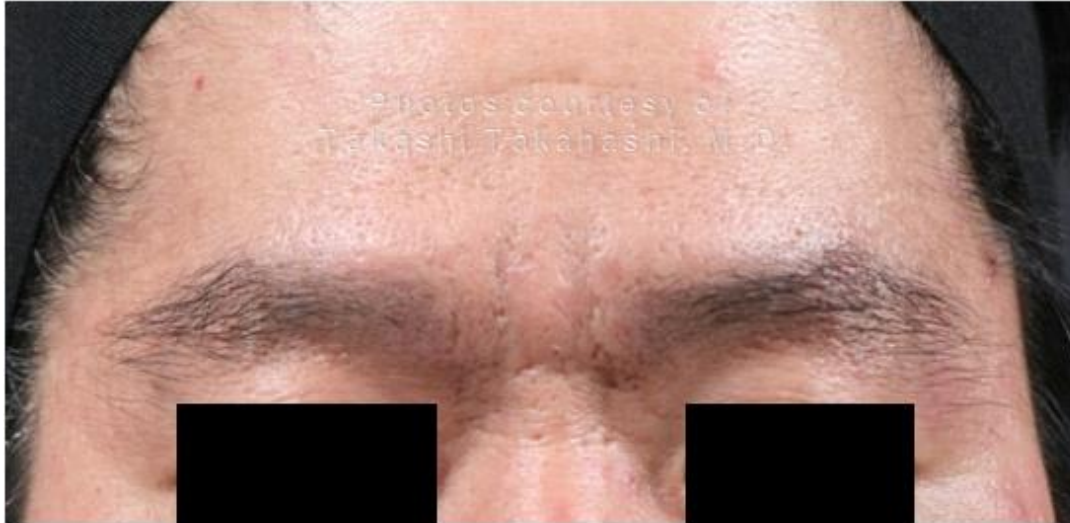1<sup>st</sup> treatment 02/10/2009

2<sup>nd</sup> treatment 03/12/2009

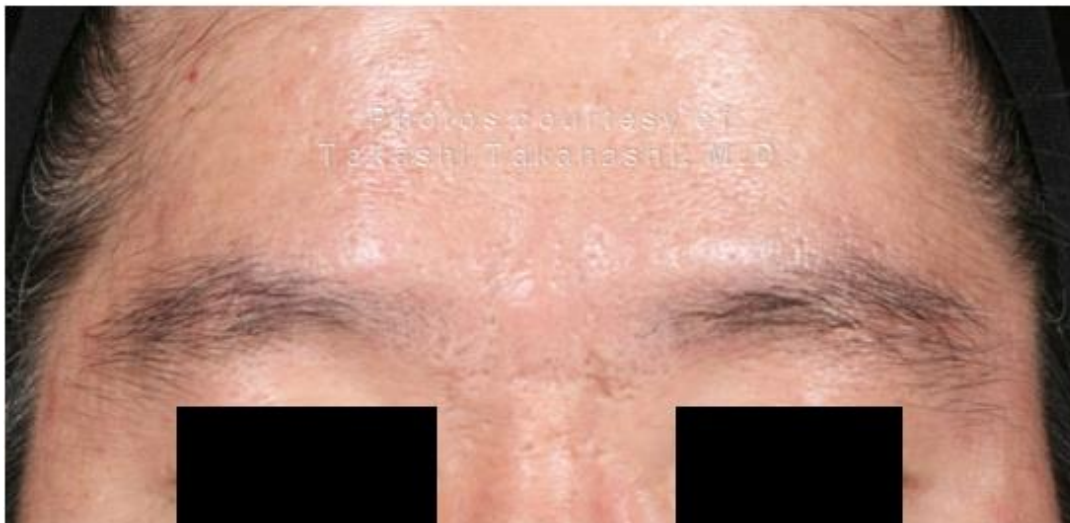3<sup>rd</sup> treatment 04/28/2009

4<sup>th</sup> treatment 06/04/2009

Full face : Bipolar Level 3 - 0.8/1.5mm, 1/2 overlap



**Before Treatment**



**36days after  
3<sup>rd</sup> Treatment**

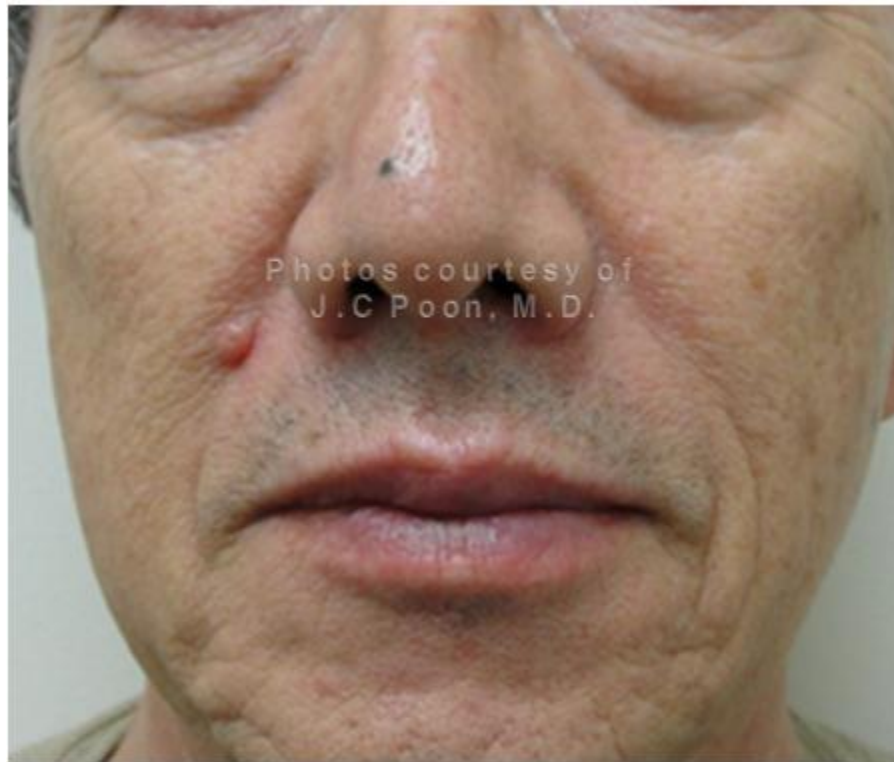# Reduction of wrinkles

**Dr. J.C Poon**

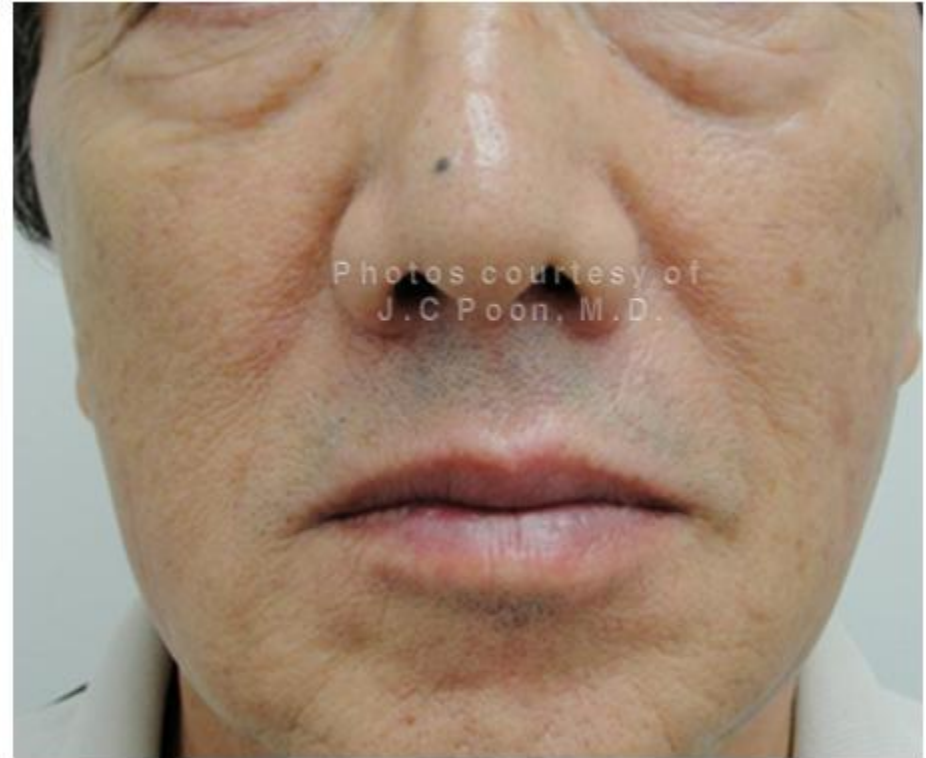*Beautiful One Lipodissolve&Laser Centre, Toronto, Canada*

**INTRAcel**

**Male**



**Before Treatment**



**1 weeks after 2<sup>nd</sup> Treatment**

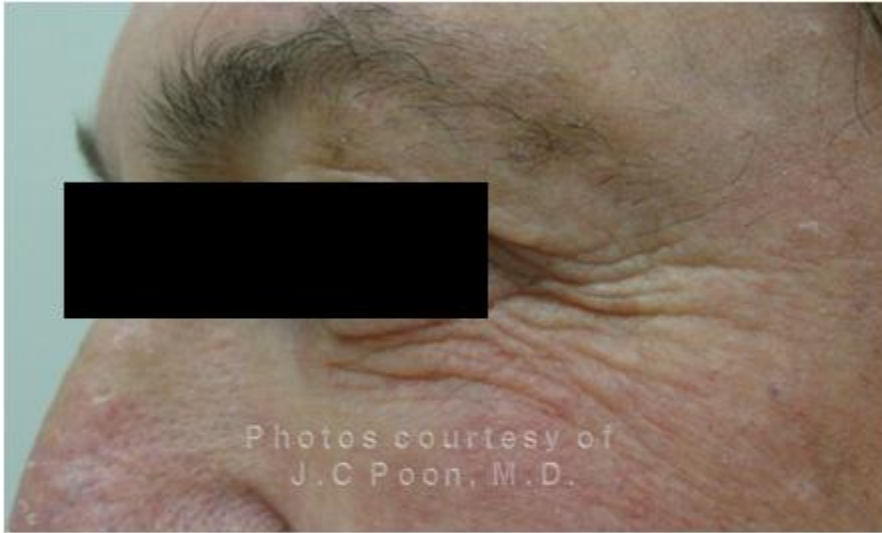# Reduction of wrinkles

**Dr. J.C Poon**

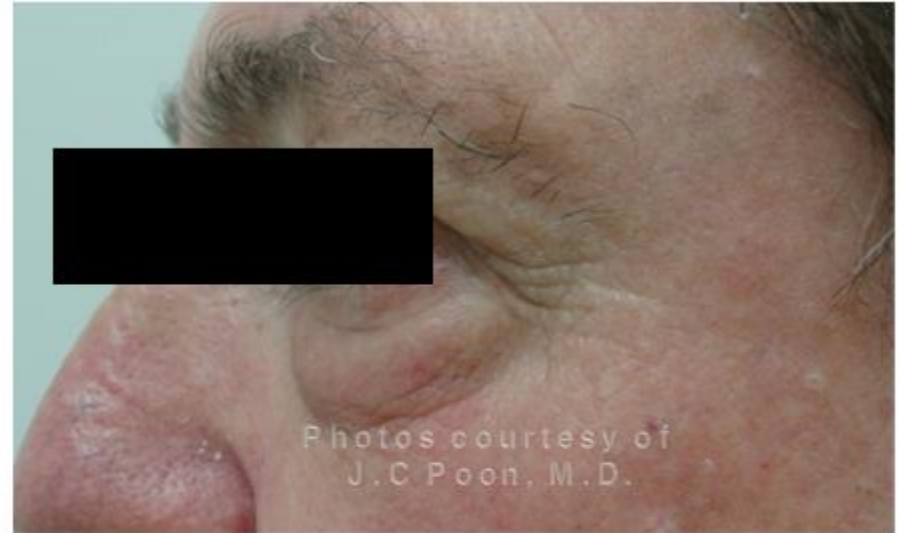*Beautiful One Lipodissolve&Laser Centre, Toronto, Canada*

**INTRAcel**

**Male**



**Before Treatment**



**1 weeks after 2<sup>nd</sup> Treatment**

## Clinical result of INTRAcel

**Tightening · Lifting**

# Tightening · Lifting Dr. Takashi Takahashi

*Takashi Takahashi Clinic, Tokyo, JAPAN*

# INTRAcE<sup>l</sup>

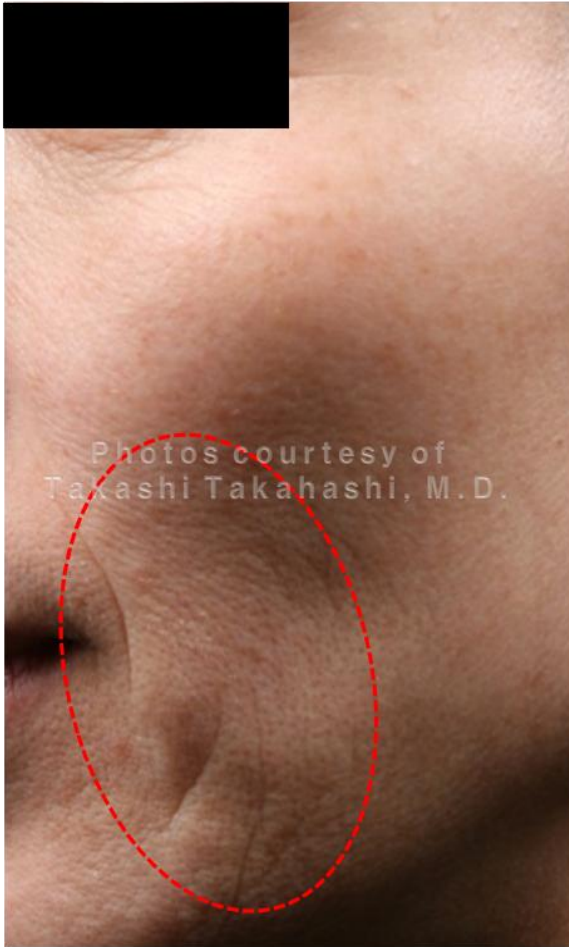
**58, Female**

1<sup>st</sup> treatment 01/08/2009

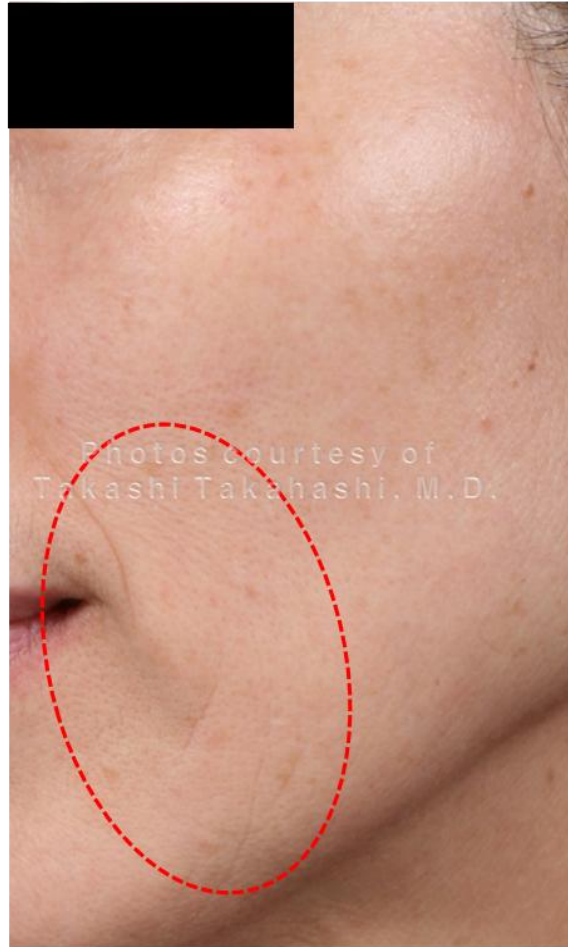2<sup>nd</sup> treatment 03/09/2009

3<sup>rd</sup> treatment 05/15/2009

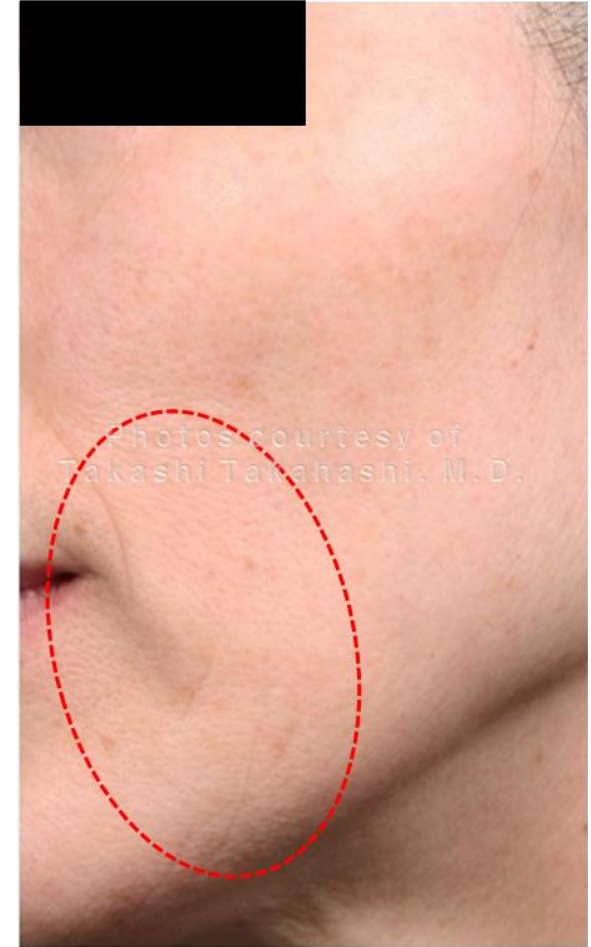Full face : Bipolar Level 2 – 1.5mm, 1pass  
Wrinkle : Bipolar Level 2 – 0.8/1.5mm, 2-3pass



**Before  
Treatment**



**60 days after  
1<sup>st</sup> Treatment**



**67 days after  
2<sup>nd</sup> Treatment**



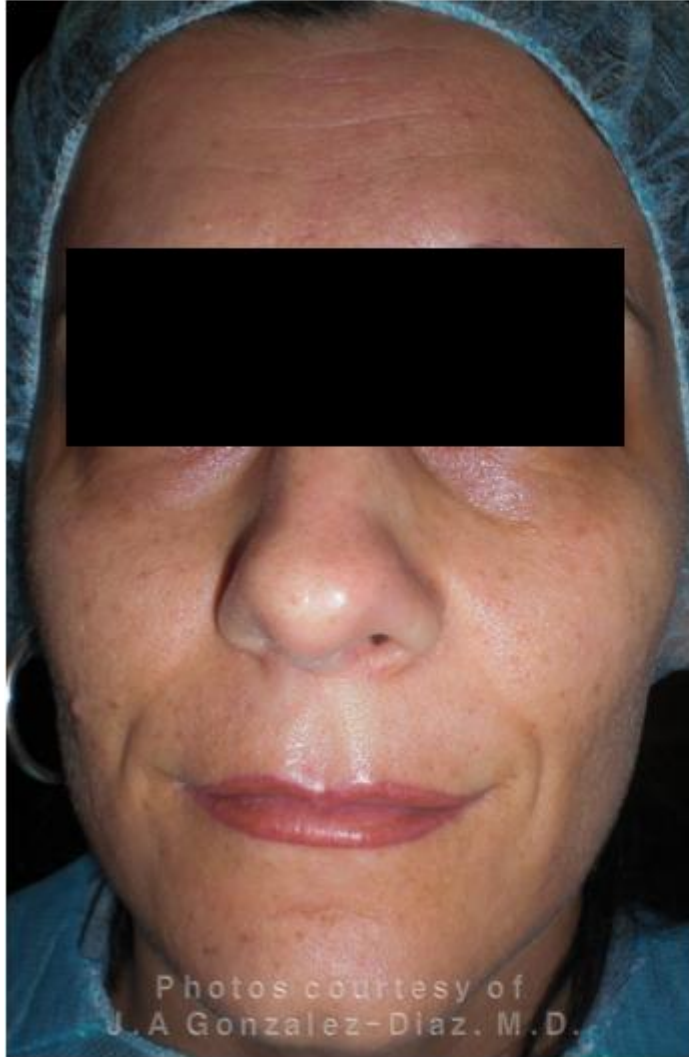# Tightening · Lifting

## Dr. J.A. Gonzalez-Diaz

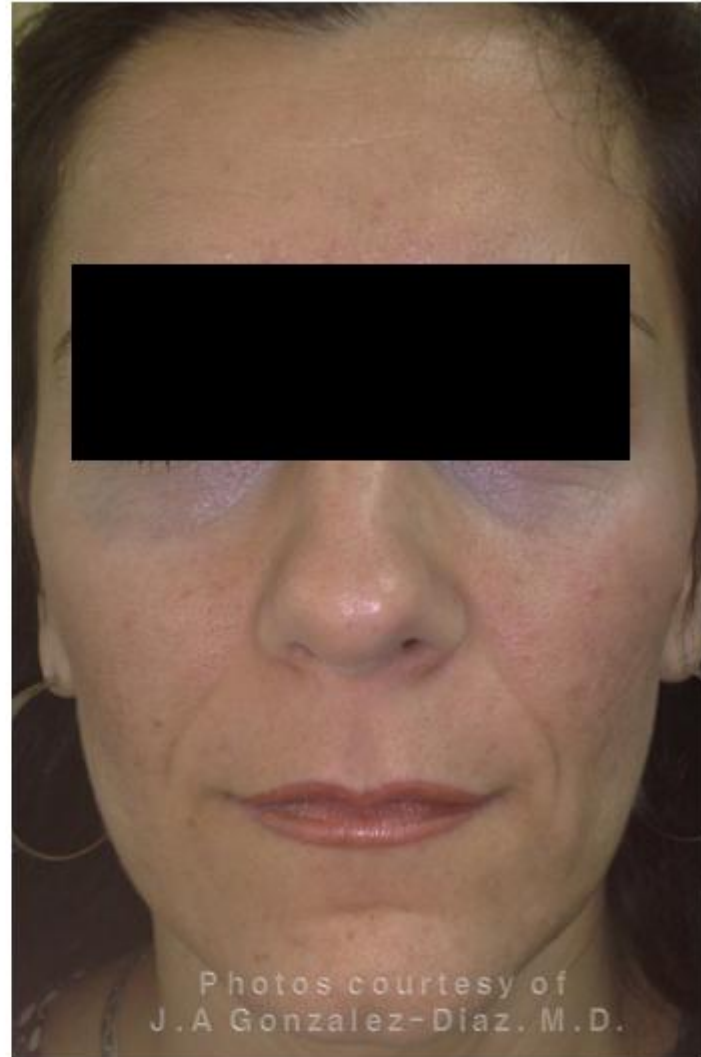
*Spanish Foundation for Aesthetic Medicine and Longevity, Barcelona, Spain*

# INTRAcel

**Female**



**Before Treatment**



**30days After 1<sup>st</sup> Treatment**

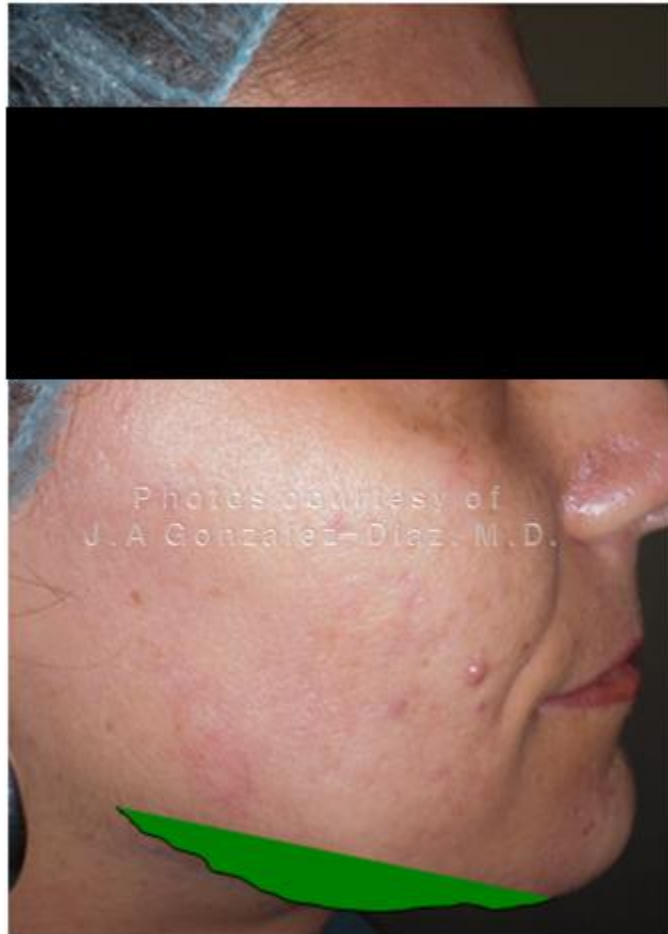
# Tightening · Lifting

## Dr. J.A. Gonzalez-Diaz

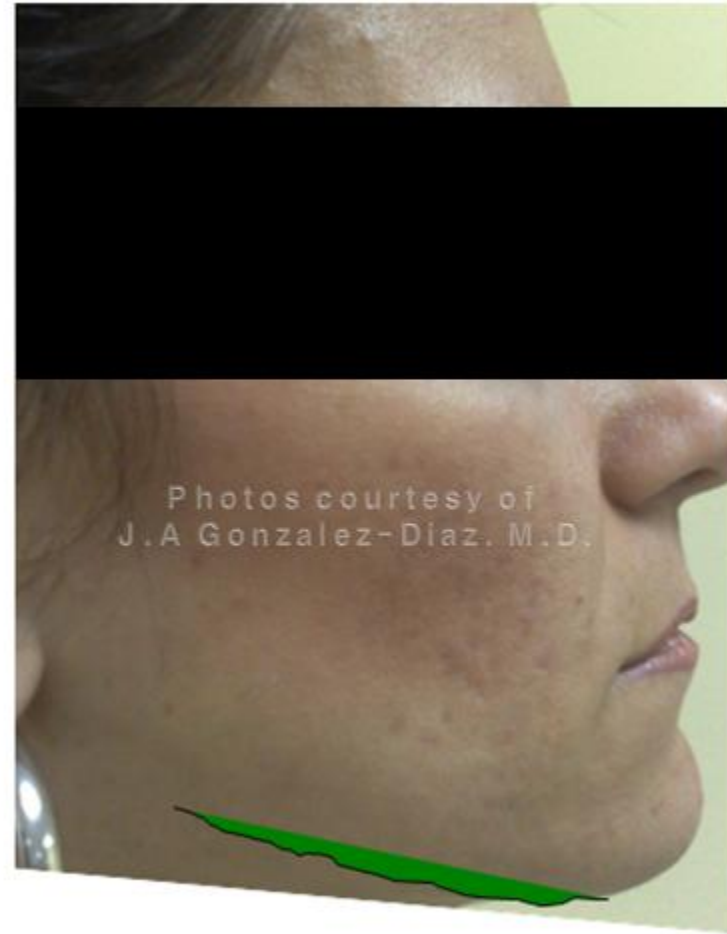
*Spanish Foundation for Aesthetic Medicine and Longevity, Barcelona, Spain*

# INTRAcel

Female



Before Treatment



30days After 1<sup>st</sup> Treatment

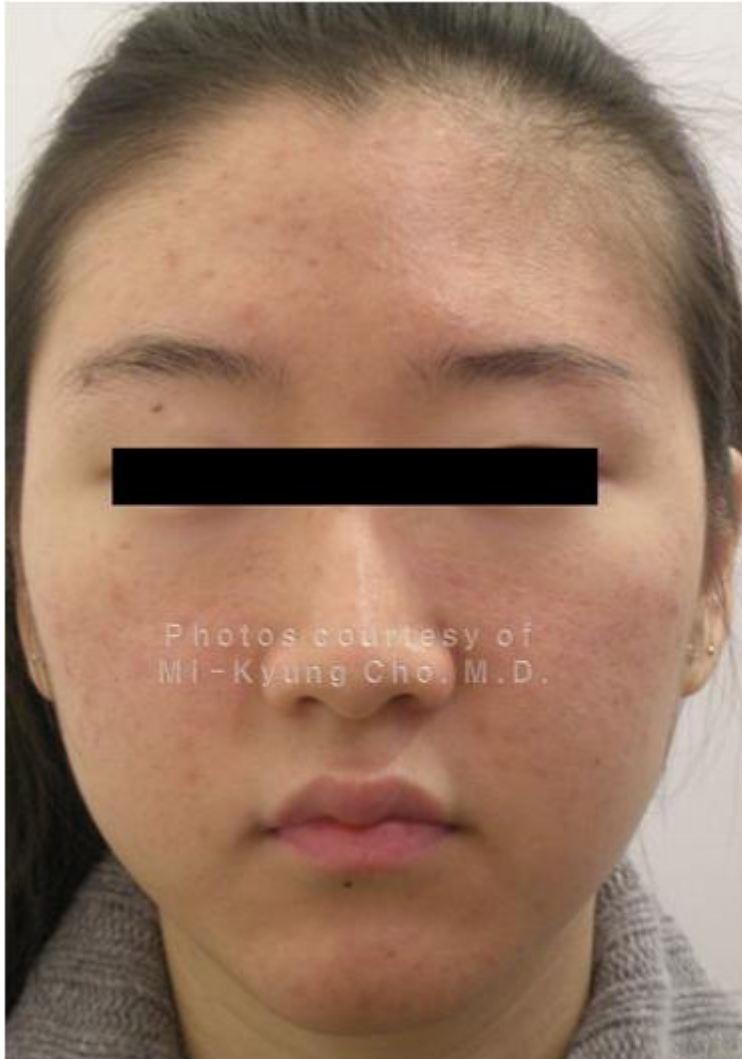# Tightening · Lifting

## Dr. Mi-Kyung Cho

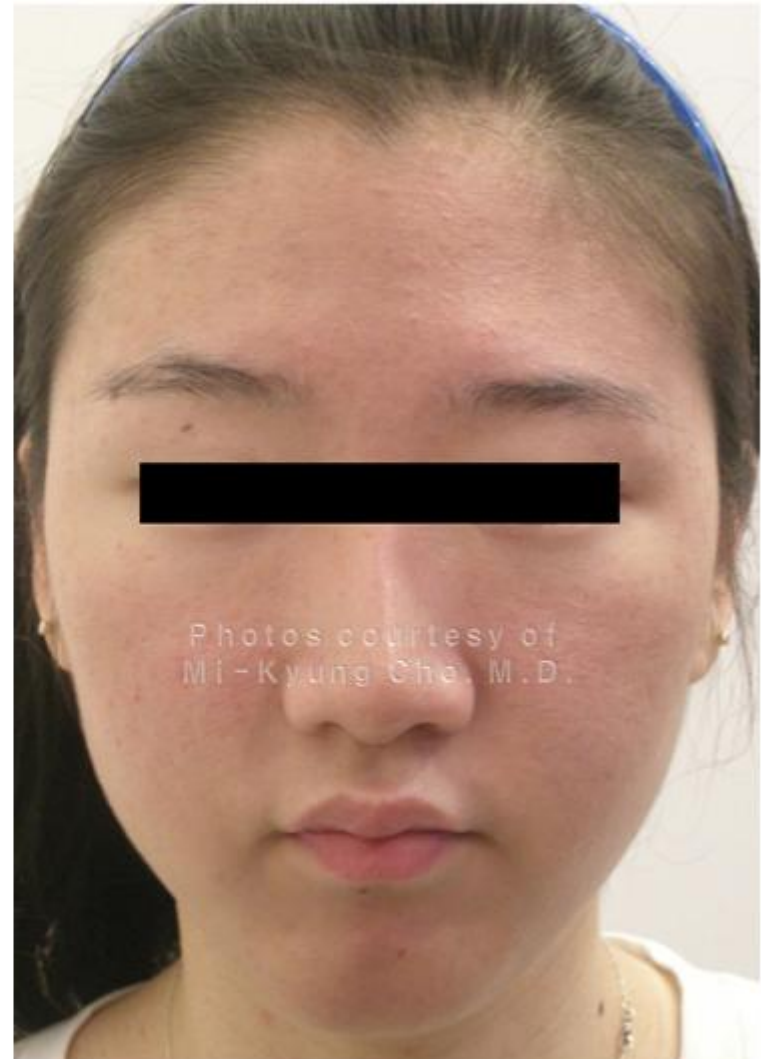*S&U Dermatology Clinic, Seoul, Korea*

# INTRAcel

Female



**Before Treatment**



**After 4<sup>th</sup> Treatment**